



## TDP-43 accumulation in inclusion body myopathy muscle suggests a common pathogenic mechanism with frontotemporal dementia

C C Wehl, P Temiz, S E Miller, G Watts, C Smith, M Forman, P I Hanson, V Kimonis and A Pestronk

*J. Neurol. Neurosurg. Psychiatry* 2008;79;1186-1189  
doi:10.1136/jnp.2007.131334

---

Updated information and services can be found at:  
<http://jnp.bmj.com/cgi/content/full/79/10/1186>

---

*These include:*

### References

This article cites 17 articles, 7 of which can be accessed free at:  
<http://jnp.bmj.com/cgi/content/full/79/10/1186#BIBL>

### Rapid responses

You can respond to this article at:  
<http://jnp.bmj.com/cgi/eletter-submit/79/10/1186>

### Email alerting service

Receive free email alerts when new articles cite this article - sign up in the box at the top right corner of the article

---

### Topic collections

Articles on similar topics can be found in the following collections

[Immunology \(including allergy\)](#) (13997 articles)  
[Memory disorders \(neurology\)](#) (1681 articles)  
[Muscle disease](#) (504 articles)  
[Neuromuscular disease](#) (1793 articles)  
[Memory disorders \(psychiatry\)](#) (2034 articles)  
[Musculoskeletal syndromes](#) (4541 articles)

---

### Notes

---

To order reprints of this article go to:  
<http://journals.bmj.com/cgi/reprintform>

To subscribe to *Journal of Neurology, Neurosurgery, and Psychiatry* go to:  
<http://journals.bmj.com/subscriptions/>

# TDP-43 accumulation in inclusion body myopathy muscle suggests a common pathogenic mechanism with frontotemporal dementia

C C Wehl,<sup>1</sup> P Temiz,<sup>2</sup> S E Miller,<sup>1</sup> G Watts,<sup>3</sup> C Smith,<sup>4</sup> M Forman,<sup>5</sup> P I Hanson,<sup>6</sup> V Kimonis,<sup>7</sup> A Pestronk<sup>1</sup>

<sup>1</sup> Department of Neurology, Washington University School of Medicine, St Louis, Missouri, USA; <sup>2</sup> Celal Bayar University School of Medicine, Department of Pathology, Manisa, Turkey; <sup>3</sup> Department of Genetics, Boston Children's Hospital, Boston, Massachusetts, USA; <sup>4</sup> University of Kentucky College of Medicine, Department of Neurology, Kentucky, USA; <sup>5</sup> Merck Research Laboratories, Boston, Massachusetts, USA; <sup>6</sup> Department of Cell Biology and Physiology, Washington University School of Medicine, St Louis, Missouri, USA; <sup>7</sup> Department of Genetics, University of California-Irvine, Irvine, California, USA

Correspondence to:  
Dr C C Wehl, Department of Neurology, Washington University School of Medicine, 660 S Euclid Avenue, St Louis, MO 63110, USA; [wehlc@neuro.wustl.edu](mailto:wehlc@neuro.wustl.edu)

Received 23 August 2007  
Revised 21 November 2007  
Accepted 6 December 2007

## ABSTRACT

TAR DNA binding protein-43 (TDP-43) is found in ubiquitinated inclusions (UBIs) in some frontotemporal dementias (FTD-U). One form of FTD-U, due to mutations in the valosin containing protein (VCP) gene, occurs with an inclusion body myopathy (IBMPFD). Since IBMPFD brain has TDP-43 in UBIs, we looked for TDP-43 inclusions in IBMPFD muscle. In normal muscle, TDP-43 is present in nuclei. In IBMPFD muscle, TDP-43 is additionally present as large inclusions within UBIs in muscle cytoplasm. TDP-43 inclusions were also found in 78% of sporadic inclusion body myositis (sIBM) muscles. In IBMPFD and sIBM muscle, TDP-43 migrated with an additional band on immunoblot similar to that reported in FTD-U brains. This study adds sIBM and hereditary inclusion body myopathies to the growing list of TDP-43 positive inclusion diseases.

TAR DNA binding protein-43 (TDP-43) is one component of the ubiquitinated inclusions in the brains of patients with frontotemporal dementias (FTD-U) and amyotrophic lateral sclerosis (ALS).<sup>1</sup> A phosphorylated form of TDP-43 was also identified to be more prevalent specifically in FTD-U tissue.<sup>1</sup> More recently, missense mutations have been identified in TOP-43 that cosegregate with autosomal dominantly inherited ALS.<sup>2-5</sup> Little is known about the function of TDP-43. It is a ubiquitously expressed, highly conserved nuclear protein that may be a transcription repressor or activator of exon skipping as well as a scaffold for nuclear bodies through interactions with survival motor neuron protein.<sup>1</sup> The significance of TDP-43 accumulation and phosphorylation is currently unclear but may relate to ubiquitin proteasome system (UPS) dysfunction. One rare form of FTD-U, inclusion body myopathy (IBM), Paget's disease of the bone and frontotemporal dementia (IBMPFD) has ubiquitinated and TDP-43 positive inclusions in affected neurons<sup>6,7</sup> while IBMPFD muscle contains rimmed vacuoles and ubiquitinated inclusions (UBIs) consistent with an IBM.<sup>8</sup>

The pathogenesis of IBM and the more common sporadic inclusion body myositis (sIBM) is unknown but may also be due to UPS dysfunction.<sup>9</sup> Affected muscle has UBIs that contain proteins, such as  $\beta$ -amyloid and phosphorylated tau, known to aggregate in CNS degenerative disorders.<sup>10,11</sup> This has led to the suggestion that sIBM is related pathophysiologically to neurodegenerative diseases. It is not known whether TDP-43 is a component of the inclusions in IBMPFD and sIBM muscle tissue. We

evaluated the localisation of TDP-43 in normal, IBMPFD and sIBM skeletal muscle tissue.

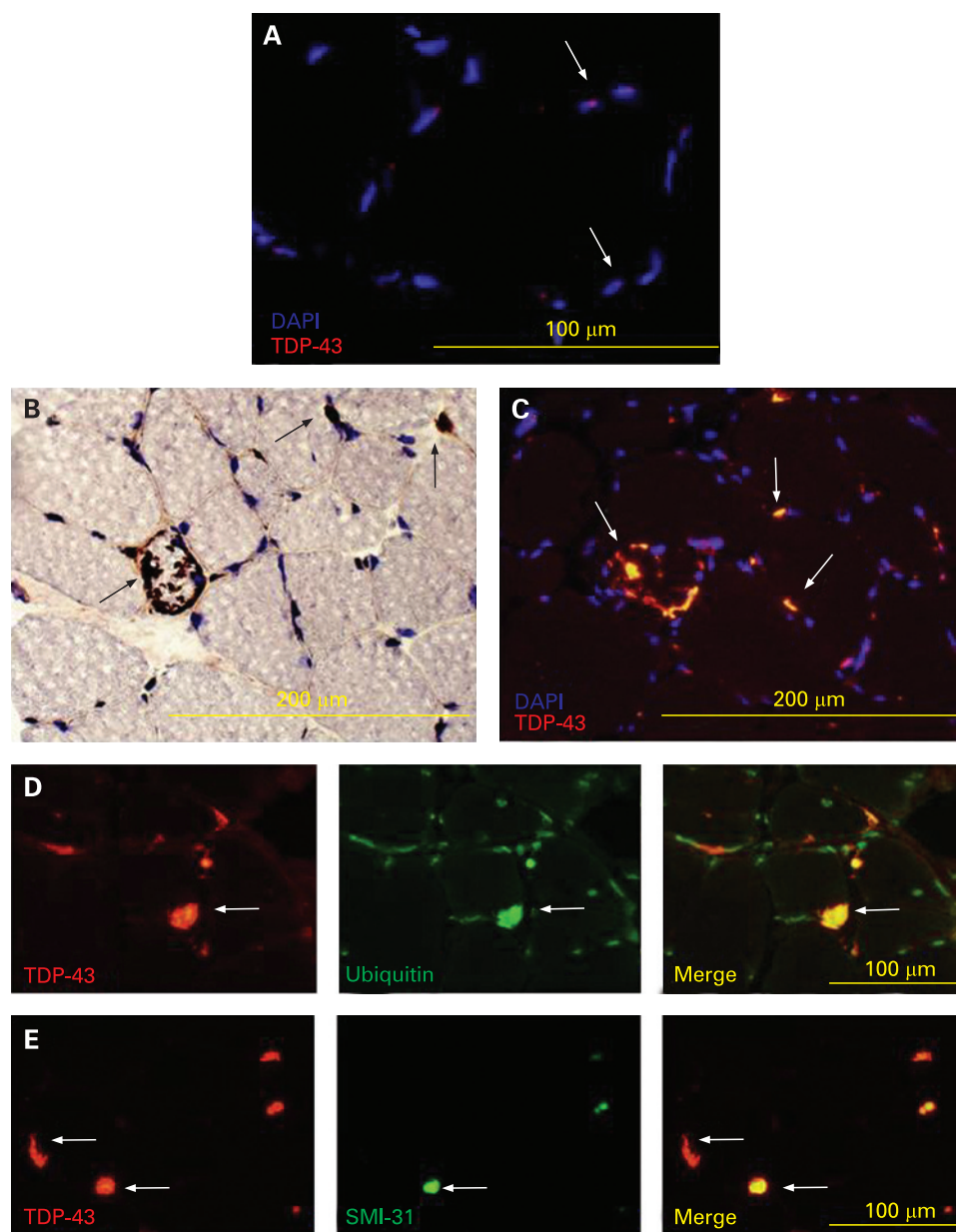
## METHODS

Patients with sIBM had typical patterns of muscle weakness on physical examination, an abnormal EMG with myopathic motor units and spontaneous activity, and a muscle biopsy with myopathic changes, rimmed vacuoles within muscle fibres and endomysial inflammation with focal invasion of muscle fibres.<sup>12</sup> Five patients with IBMPFD and missense mutations in the p97/valosin containing protein (VCP) gene (four with R155H and one with N387H)<sup>13</sup> were participants in the IRB approved study. All muscle biopsies were processed and evaluated in the Washington University Neuromuscular Laboratory. Cryostat sections of rapidly frozen muscle were processed for muscle histochemistry and immunocytochemistry in our standard fashion.<sup>8,13</sup> The presence of vacuoles was evaluated via routine histochemical methods, such as haematoxylin and eosin or modified Gomori-trichrome stains. Immunocytochemistry for each antibody was performed on tissue from patients and compared with normal tissue controls processed simultaneously. Primary antibodies used in this study were directed against CD8 (clone M7103), phosphorylated neurofilaments or other phosphorylated epitopes (SMI-31; Covance, Berkeley, California, USA), FK2 antibody to ubiquitinated proteins (PW8810-0500; BioMol, Plymouth Meeting, Pennsylvania, USA), TDP-43 antibodies: rabbit polyclonal antibody (ProteinTech Antibody Group, Chicago, Illinois, USA) and mouse monoclonal antibody 2E2-D3 (Abnova, Taipei, Taiwan). Double labelling immunofluorescence was performed as previously described using Alexa Fluor 488 and 594 conjugated secondary antibodies (Molecular Probes; Eugene, Oregon, USA). Immunoperoxidase was performed as previously described using peroxidase conjugated secondary antibodies (Sigma, St Louis, Missouri, USA). The specificity of TDP-43 immunostaining was confirmed with two different commercial antibodies and incubation with secondary antibody alone (either fluorescent or peroxidase conjugated). Immunoblots were performed as previously described.<sup>14</sup>

## RESULTS

In four normal muscle biopsies, TDP-43 was localised within scattered myonuclei with no evidence of sarcoplasmic staining (fig 1A). In

**Figure 1** (A) Normal muscle immunostained with anti-TAR DNA binding protein-43 (TDP-43) antibody and counterstained with DAPI to allow visualisation of nuclei. The figure is an overlay of anti-TDP-43 and DAPI images. Arrows denote blue nuclei with TDP-43 (red dots) in scattered myonuclei. (B) Inclusion body myopathy, Paget's disease of the bone and frontotemporal dementia (IBMPFD) tissue from patients immunostained with anti-TDP-43 (brown) and counterstained with Congo red to allow visualisation of nuclei and myofibres. Arrows denote large inclusions, some of which are peripherally based. (C) Overlay of anti-TDP-43 (orange) and DAPI (blue) of IBMPFD patient tissue. Note that large peripheral inclusions do not localise within nuclei (arrows). (D) IBMPFD patient tissue co-immunostained with anti-TDP-43 (red) and FK2 (green). Note that TDP-43 inclusions colocalise with FK2 (ubiquitinated proteins) (arrows). (E) IBMPFD patient tissue co-immunostained with anti-TDP-43 (red) and SMI-31, an antibody against phosphorylated tau epitopes (green). Note that some TDP-43 inclusions colocalise with SMI31 (closed arrows) and others do not (open arrows).



contrast, all IBMPFD muscle tissue had large peripherally based TDP-43 positive sarcoplasmic inclusions that did not localise to myonuclei (fig 1B, 1C). These inclusions consistently colocalised with FK2, an antibody that recognises ubiquitinated proteins (fig 1D) and in some cases with other proteins known to aggregate. SMI-31 binding was less prominent than TDP-43 in IBMPFD muscle tissue (fig 1E).

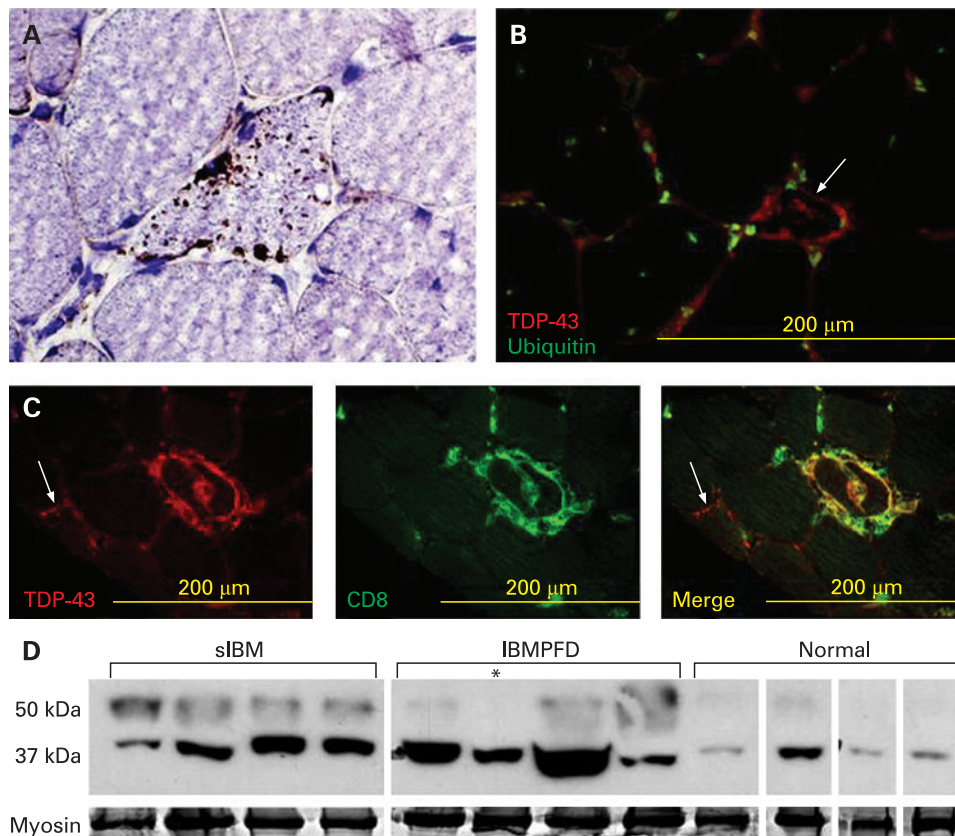
A distinctively different pattern of TDP-43 immunostaining was seen in 21 of 27 sIBM muscle. TDP-43 immunostained multiple small sarcoplasmic aggregates, most commonly in small angular muscle fibres (fig 2A). These inclusions did not colocalise with myonuclei. TDP-43 was also present in debris surrounding some rimmed vacuoles (fig 2A). The TDP-43 inclusions in sIBM were usually ubiquitin negative (fig 2B), but occasionally colocalised with FK2. TDP-43 also colocalised with T cells at sites of inflammatory infiltrates (fig 2C). In contrast with sIBM, TDP-43 positive inclusions were found in only 1 of 12 steroid responsive polymyositis patient biopsies.

Immunoblots of normal, IBMPFD and sIBM patient tissue with an antibody to TDP-43 demonstrated an increase in TDP-43 immunoreactivity present at 43 kDa as well as a higher migrating band similar to the phosphorylated form seen in FTD-U patient tissue (fig 2D).

## DISCUSSION

Disruptions in the UPS may be associated with the pathogenesis of several degenerative disorders. In particular, IBM muscle and FTD-U brain have UBIs that contain aggregated proteins. However, the principal molecular constituents of the UBIs seen in these diseases have been incompletely defined. Recent studies have identified TDP-43 as a component of the UBIs in FTD-U, including IBMPFD, and ALS brain tissue.<sup>1-7</sup> As IBMPFD muscle also has UBIs, we examined the localisation of TDP-43 in normal, sIBM and IBMPFD patient skeletal muscle. We found that TDP-43 localised to myonuclei in normal muscle but, in IBMPFD and sIBM muscle, TDP-43 was additionally present as sarcoplasmic inclusions. This is associated with an increase in

## Short report



**Figure 2** (A) Sporadic inclusion body myositis (sIBM) tissue from patients, immunostained with anti-TAR DNA binding protein-43 (TDP-43) (brown) and counterstained with Congo red to allow visualisation of nuclei and myofibres. TDP-43 inclusions are small, in angular fibres and occasionally surround rimmed vacuoles. (B) Overlay of sIBM patient biopsy immunostained with TDP-43 (red) and FK2, for ubiquitinated proteins (green). TDP-43 inclusions do not colocalise with ubiquitin. (C) sIBM patient tissue co-immunostained with anti-TDP-43 (red) and anti-CD8 (green at focal sites of inflammation). Note the colocalisation of TDP-43 and CD8. This is in contrast with an adjacent fibre (arrow) with sarcoplasmic TDP-43 inclusions that does not co-localise with CD8. (D) Muscle tissue from sIBM, inclusion body myopathy, Paget's disease of the bone and frontotemporal dementia (IBMPFD) and normal patient biopsies were homogenised and separated by sodium dodecyl sulphate-polyacrylamide gel electrophoresis. The subsequent gel was transferred to nitrocellulose and immunoblotted with an antibody to TDP-43. Normal tissue has a discrete band at 43 kDa consistent with TDP-43, while sIBM and IBMPFD have a more prominent band and also a higher migrating band. Myosin is shown as a loading control. All tissues are from flash frozen biopsies except the lane noted with an asterisk which is from autopsy muscle. All bands are from the same autoradiograph and moved for presentation purposes.

TDP-43 protein levels as well as a higher molecular weight band seen in sIBM and IBMPFD patient muscle tissue via immunoblot when compared with normal patient tissue. A similar higher molecular weight band was identified as phosphorylated TDP-43 in patients with FTD-U and ALS.<sup>1</sup> Whether the band seen in IBMPFD and sIBM muscle tissue is the same or another post-translationally modified form (ie, ubiquitinated) is not known.

TDP-43 inclusions were present in 100% of IBMPFD and 78% of sIBM patient muscle biopsies, while 0% of normal muscle and 8% of steroid responsive polymyositis patient muscle biopsies had similar TDP-43 inclusions. This suggests that TDP-43 immunohistochemistry may be helpful in confirming the diagnosis of sIBM. At present, the most reliable antibody marker for the diagnosis of sIBM is SMI-31 (an antibody against phosphorylated tau epitopes) which is not present in all sIBM biopsies and found in other diseased muscle tissue.<sup>15</sup> For example, in our hands, SMI-31 positive aggregates are present in 66% of sIBM patients compared with 17% of steroid responsive polymyositis patients (unpublished observations).

It is notable that the TDP-43 immunostaining pattern was different when comparing sIBM and IBMPFD muscle. sIBM had

small punctuate TDP-43 positive inclusions throughout the sarcoplasm that occasionally colocalised with ubiquitin. IBMPFD muscle had large peripherally based TDP-43 positive inclusions that always colocalised with ubiquitin. Both sIBM and IBMPFD patient muscle had evidence of a higher molecular weight TDP-43 species on immunoblot.

Our findings in skeletal muscle are similar to those found in CNS disease.<sup>1</sup> TDP-43 inclusions in FTD-U and ALS are cytoplasmic, similar to the predominantly sarcoplasmic inclusions in IBM muscle. The presence of ubiquitinated TDP-43 in disparate tissues (ie, IBMPFD muscle and brain) in which the only commonality is mutant VCP, suggests that VCP dysfunction may play a role in TDP-43 aggregation.

TDP-43 contains RNA binding motifs that may be associated with its function. Interestingly, another hereditary IBM, oculopharyngeal muscular dystrophy, is caused by mutations in another RNA binding protein, PABPN1.<sup>16</sup> Mutant PABPN1 forms intranuclear inclusions that contain ubiquitin and polyadenylated mRNA.<sup>17</sup> It is not known whether a similar process occurs with TDP-43 in sIBM and IBMPFD.

Diseases that develop TDP-43 inclusions include FTD-U, ALS, IBMPFD and sIBM,<sup>17</sup> suggesting that similar pathogenic

mechanisms may be present. Additional studies will be needed to further define the role of these proteins and their dysregulation in central nervous system and skeletal muscle tissue.

**Competing interests:** None.

**Ethics approval:** Obtained.

## REFERENCES

1. **Neumann M**, Sampathu DM, Kwong LK, *et al*. Ubiquitinated TDP-43 in frontotemporal lobar degeneration and amyotrophic lateral sclerosis. *Science* 2006;**314**:130–3.
2. **Yokoseki A**, Shiga A, Tan CF, *et al*. TDP-43 mutation in familial amyotrophic lateral sclerosis. *Ann Neurol* 2008;**63**:538–42.
3. **Gitcho MA**, Baloh RH, Chakraverty, *et al*. TDP-43 A31ST mutation in familial motor neuron disease. *Ann Neurol* 2008;**63**:535–8.
4. **Kabashi E**, Valdmanis PN, Dion P, *et al*. TARDBP mutations in individuals with sporadic and familial amyotrophic lateral sclerosis. *Nat Genet* 2008;**40**:572–4.
5. **Sreedharan J**, Blair IP, Tripathi VB, *et al*. TDP-43 mutations in familial and sporadic amyotrophic lateral sclerosis. *Science* 2008;**319**:1668–72.
6. **Forman MS**, Mackenzie IR, Cairns NJ, *et al*. Novel ubiquitin neuropathology in frontotemporal dementia with valosin-containing protein gene mutations. *J Neuropathol Exp Neurol* 2006;**65**:571–81.
7. **Neumann M**, Mackenzie IR, Cairns NJ, *et al*. TDP-43 in the ubiquitin pathology of frontotemporal dementia with VCP gene mutations. *J Neuropathol Exp Neurol* 2007;**66**:152–7.
8. **Hubbers CU**, Clemen CS, Kesper K, *et al*. Pathological consequences of VCP mutations on human striated muscle. *Brain* 2007;**130**:381–93.
9. **Askanas V**, Engel WK. Inclusion-body myositis: a myodegenerative conformational disorder associated with Abeta, protein misfolding, and proteasome inhibition. *Neurology* 2006;**66**(Suppl 1):S39–48.
10. **Askanas V**, Alvarez RB, Engel WK. beta-Amyloid precursor epitopes in muscle fibers of inclusion body myositis. *Ann Neurol* 1993;**34**:551–60.
11. **Askanas V**, Engel WK, Bilak M, *et al*. Twisted tubulofilaments of inclusion body myositis muscle resemble paired helical filaments of Alzheimer brain and contain hyperphosphorylated tau. *Am J Pathol* 1994;**144**:177–87.
12. **Dalakas MC**. Sporadic inclusion body myositis—diagnosis, pathogenesis and therapeutic strategies. *Nat Clin Pract Neurol* 2006;**2**:437–47.
13. **Watts GD**, Wymer J, Kovach MJ, *et al*. Inclusion body myopathy associated with Paget disease of bone and frontotemporal dementia is caused by mutant valosin-containing protein. *Nat Genet* 2004;**36**:377–81.
14. **Weihl CC**, Dalal S, Pestronk A, *et al*. Inclusion body myopathy-associated mutations in p97/VCP impair endoplasmic reticulum-associated degradation. *Hum Mol Genet* 2006;**15**:189–99.
15. **van der Meulen MF**, Hoogendijk JE, Moons KG, *et al*. Rimmed vacuoles and the added value of SMI-31 staining in diagnosing sporadic inclusion body myositis. *Neuromuscul Disord* 2001;**11**:447–51.
16. **Brais B**, Bouchard JP, Xie YG, *et al*. Short GCG expansions in the PABP2 gene cause oculopharyngeal muscular dystrophy. *Nat Genet* 1998;**18**:164–7.
17. **Calado A**, Tome FM, Brais B, *et al*. Nuclear inclusions in oculopharyngeal muscular dystrophy consist of poly(A) binding protein 2 aggregates which sequester poly(A) RNA. *Hum Mol Genet* 2000;**9**:2321–8.