

Clinical and Pathological Continuum of Multisystem TDP-43 Proteinopathies

Felix Geser, MD, PhD; Maria Martinez-Lage, MD; John Robinson, BS; Kunihiro Uryu, PhD; Manuela Neumann, MD; Nicholas J. Brandmeir, MS; Sharon X. Xie, PhD; Linda K. Kwong, PhD; Lauren Elman, MD; Leo McCluskey, MD; Chris M. Clark, MD; Joe Malunda; Bruce L. Miller, MD; Earl A. Zimmerman, MD; Jiang Qian, MD; Vivianna Van Deerlin, MD, PhD; Murray Grossman, MD, EdD; Virginia M.-Y. Lee, PhD, MBA; John Q. Trojanowski, MD, PhD

Objective: To determine the extent of transactivation response DNA-binding protein with a molecular weight of 43 kDa (TDP-43) pathology in the central nervous system of patients with clinically and autopsy-confirmed diagnoses of frontotemporal lobar degeneration with and without motor neuron disease and amyotrophic lateral sclerosis with and without cognitive impairment.

Design: Performance of immunohistochemical whole-central nervous system scans for evidence of pathological TDP-43 and retrospective clinical medical record review.

Setting: An academic medical center.

Participants: We included 64 patients with clinically and pathologically confirmed frontotemporal lobar degeneration with ubiquitinated inclusions with or without motor neuron disease and amyotrophic lateral sclerosis with or without cognitive impairment.

Main Outcome Measure: Neuronal and glial TDP-43 pathology.

Results: We found evidence of neuronal and glial TDP-43 pathology in all disease groups throughout the neuraxis, albeit with variations in the frequency, morphology, and distribution of TDP-43 lesions. Moreover, the major clinical manifestations (eg, cognitive impairments, motor neuron signs, extrapyramidal symptoms, neuropsychiatric features) were reflected by the predominant distribution and burden of TDP-43 pathology.

Conclusion: These findings strongly suggest that amyotrophic lateral sclerosis, frontotemporal lobar degeneration with amyotrophic lateral sclerosis or motor neuron disease, and frontotemporal lobar degeneration with ubiquitinated inclusions are different manifestations of a multiple-system TDP-43 proteinopathy linked to similar mechanisms of neurodegeneration.

Arch Neurol. 2009;66(2):180-189

FRONTOTEMPORAL LOBAR DEGENERATION (FTLD) with ubiquitinated inclusions (FTLD-U) or “ubiquitin-only dementia” is characterized by degeneration of the neocortex and hippocampus with ubiquitin-positive but tau- and α -synuclein-negative inclusions. Using ubiquitin or novel monoclonal antibodies generated from FTLD-U brains, at least 4 distinct morphological subtypes of FTLD-U have been described.¹⁻³ Subtype 1 is characterized by frequent long neuritic profiles predominantly in the superficial cortical layers; subtype 2, by neuronal cytoplasmic inclusions in superficial and deep cortical layers; and subtype 3, by an abundance of small neuritic profiles and neuronal cytoplasmic inclusions (often ring shaped) predominantly in the superficial cortical layers.¹ Subtype 4 refers to the unique neuropathology found in FTLD with valo-

sin-containing protein gene mutations featuring mainly numerous neuronal intranuclear inclusions and no dentate gyrus inclusions.² The cardinal clinical features of all FTLDs are progressive changes in executive function and behavior often with disinhibition and language difficulties. Frontotemporal lobar degeneration is the second most common cause of early-onset dementia after Alzheimer disease. Notably, the neuropathology underlying FTLD is a tauopathy in approximately 45% of patients, while in about 50% of patients, the underlying pathology is FTLD-U. When FTLD-U is associated with amyotrophic lateral sclerosis (ALS) or motor neuron disease (MND) either clinically or pathologically, the term *FTLD-MND* is used.² Further, ALS may be associated with cognitive impairments characteristic of FTLD, and it has been speculated that ALS and FTLD are different manifestations of a single disorder.⁴

Author Affiliations are listed at the end of this article.

However, the presence of additional clinical features has usually led to the exclusion of a diagnosis of classic ALS and instead is regarded as an ALS-Plus syndrome according to El Escorial clinical diagnostic criteria.⁵ Thus, the association of typical ALS followed by progressive cognitive impairments culminating in dementia often is referred to as ALS plus dementia (ALS-D).

In 2006, the ubiquitin inclusions of FTLD-U as well as those in ALS were shown to be formed by the nuclear protein transactivation response DNA-binding protein with a molecular weight of 43 kDa (TDP-43), thereby supporting the notion that FTLD-U and ALS are related mechanistically and form a new class of neurodegenerative protein misfolding disorders, ie, TDP-43 proteinopathies.⁴ Moreover, there is increasing evidence that pathological TDP-43 affects widespread regions of the neuraxis as indicated by recent studies of ALS and FTLD with MND cases.^{3,6-10}

It is known that mutations in the tau (*MAPT*) gene are pathogenic for familial tauopathies with FTLD and mutations in the progranulin gene (*PRGN*) are pathogenic for TDP-43-associated FTLD-U. Thus, TDP-43 pathology provides a mechanistic link between sporadic FTLD-U and familial FTLD-U caused by *PGRN* mutations, as well as between these forms of FTLD and sporadic and familial forms of ALS, some of which have been shown to be caused by mutations in the TDP-43 (*TARDBP*) gene.¹¹

Based on these new insights into the pathobiology of TDP-43, we hypothesized that ALS, ALS-D/FTLD-MND, and FTLD-U reflect a continuum of a broad clinicopathological spectrum of a multisystem degeneration sharing similar disease mechanisms linked to pathological TDP-43. To test this hypothesis, we performed immunohistochemical whole-central nervous system (CNS) scans focused on FTLD-U and FTLD-MND and incorporated similar data from our recently published large series of ALS and ALS-D.^{6,7} Further, we also compared these pathological findings with the clinical features of these disorders. We found that TDP-43 pathology affects widespread regions of the CNS in FTLD-MND and FTLD-U, as well as in ALS and ALS-D, although the preponderance of the burden and distribution of TDP-43 pathology does reflect the broad clinical manifestations of each disorder. Thus, taken together as a group, we infer that these disorders represent a single multiple-system neurodegenerative disorder that can be designated as a multisystem TDP-43 proteinopathy.

METHODS

STUDY SUBJECTS

Patients who underwent autopsy in the Center for Neurodegenerative Disease Research (CNDR) from 1985 to 2007 and showed tau- and α -synuclein-negative but ubiquitin-positive inclusions coupled with signs of degeneration in various CNS regions were identified in the CNDR Brain Bank at the University of Pennsylvania using the CNDR Brain Bank database. The cases were categorized based on the clinical manifestations according to published clinical diagnostic criteria (ie, El Escorial⁵ or Neary et al¹²) as follows: ALS (with MND but no dementia), frontotemporal dementia (FTD) (with executive behavior or language impair-

ments but no MND), or a combination of both FTD and MND, defined as the "mixed" group. The subjects were longitudinally followed up in the University of Pennsylvania AD Center Core, ALS Center, or Memory Disorder Center; the University of California at San Francisco Memory and Aging Center; or the Albany Medical Center AD Center. Retrospective clinical medical record review was performed to obtain clinical information and to classify the subjects according to clinical criteria. However, a preference was given for early recognition of any clinical manifestation of underlying pathology, and thus, mild symptoms and signs were considered inclusive for classification and analysis. Subsequently, in the mixed group, 4 of 18 patients who had FTD and mild motor neuron signs did not meet El Escorial criteria for any category of ALS, and 5 patients who had ALS and behavioral/social or language symptoms did not meet criteria for full-blown dementia. Informed consent for autopsy was obtained in all cases from the patients or legal representative in accordance with Pennsylvania, California, and New York state law as well as protocols approved by the University of Pennsylvania, University of California at San Francisco, and Albany Medical Center local institutional review boards. The presence or absence of a family history of MND and/or dementia and the clinical involvement of main functional domains of the patients were obtained from the medical records (M.M.-L., E.A.Z., L.M., L.E., and F.G.).

All CNS samples studied herein came from the University of Pennsylvania CNDR Brain Bank following neuropathology diagnostic assessment, as described.⁴ The eTable (<http://www.archneuro.com>) shows the number of examined brain areas both according to the clinical diagnosis and FTLD-U subtype. The data on the whole-CNS scans of TDP-43 pathology in the ALS with and without cognitive impairment cases and 2 FTD-MND cases previously published by our group^{6,7} were included and supplemented by an additional ALS case. In cases with a sufficient burden of ubiquitinated inclusion, pathology in frontotemporal neocortical areas for subtype analysis was classified according to Sampathu et al¹ (FTLD-U subtypes 1, 2, or 3).

IMMUNOHISTOCHEMISTRY

The cases were fully examined by routine diagnostic techniques, as described.^{6,7} Briefly, fresh tissues from multiple CNS areas as available were fixed in 10% neutral buffered formalin or 70% ethanol with 150 mmol of sodium chloride, paraffin embedded, and cut into 6- μ m sections. Sections were stained with hematoxylin-eosin followed by immunohistochemistry, which was performed as previously described using (1) the avidin-biotin complex detection method (VECTASTAIN ABC kit; Vector Laboratories, Burlingame, California) or (2) BioGenex Super Sensitive MultiLink IHC Detection System Kit (BioGenex Laboratories, San Ramon, California) with 3,3'-diaminobenzidine as the chromogen. The following primary antibodies were used: anti-tau mouse monoclonal antibody (mAb) (1:500; Sigma-Aldrich, St Louis, Missouri), mouse antipaired helical filament mAb (1:1000; a gift of Peter Davies, PhD), mouse antiubiquitin mAb (1510, 1:100 000; Chemicon, Temecula, California, and 1:600; Sigma-Aldrich), rabbit polyclonal antiubiquitin (1:1000; DakoCytomation, Glostrup, Denmark), rabbit polyclonal anti-TDP-43 (1:4500; Protein-Tech Group, Chicago, Illinois), mouse anti-TDP-43 mAb (1:10 000; Novus Biologicals, Littleton, Colorado), rabbit polyclonal anti- α -synuclein (1:20; Chemicon), mouse anti- α -synuclein mAb 303 (1:4000; generated in CNDR), mouse anti-HLA-DR mAb (1:5000; DakoCytomation), and rabbit polyclonal anti-gial fibrillary acidic protein mAb (1:5000; DakoCytomation). Sections stained for ubiquitin, TDP-43, and HLA-DR were pretreated by boiling in citrate antigen unmasking solution (Vector Laboratories) using a pressure cooker and microwave, and

Table 1. Summary of Patient Characteristics According to Clinical Diagnosis

Clinical Diagnosis	Sample Size	Male: Female Ratio	Family History, %	PGRN Genotyping Status	Median (IQR)			
					Disease Duration, y	Age at Death, y	PMI, h	Brain Weight, g
ALS	26	1:0.6	7.7	0 Mutations; 1 variant	2.0 (2.0-4.0)	59.5 (52.5-65.8)	14.8 (9.0-19.3)	1419.5 (1312.0-1539.8)
Mixed	18	1:0.6	27.8	1 Mutation; 1 variant	2.0 (1.0-3.3)	57.0 (54.5-67.5)	8.0 (6.3-18.0)	1230.0 (1182.5-1317.8)
FTD	20	1:1.9	62.5	4 Mutations; 4 variants	7.0 (5.0-10.0)	72.0 (64.3-77.0)	13.0 (8.9-19.0)	1010.5 (908.5-1200.0)
<i>P</i> value		.15 ^a	<.001 ^a		<.001 ^b	.001 ^b	.24 ^b	<.001 ^b

Abbreviations: ALS, amyotrophic lateral sclerosis; FTD, frontotemporal dementia; IQR, interquartile range; PMI, postmortem interval.

^a*P* value for any difference: χ^2 test (or Fisher exact test).

^b*P* value for any difference: Kruskal-Wallis H test.

those stained for α -synuclein were pretreated with formic acid. Double-labeling immunofluorescence using Alexa Fluor 488 and 594 conjugated secondary antibodies (Molecular Probes, Eugene, Oregon) was performed as previously described.^{4,6,7}

QUANTITATION OF PATHOLOGY

TDP-43 pathology severity was graded using a 4-point arbitrary ordinal scale (0=none, 1=rare/mild, 2=occasional/moderate, 3=numerous/severe) by several of us (F.G., K.U., M.M.-L., and J.Q.T.) without prior knowledge of the clinical diagnosis. Inclusions were also categorized based on their different morphologies. TDP-43 pathology in white and gray matters was given individual scores. Neurodegeneration was rated based on hematoxylin-eosin staining using a similar 4-point scale (ie, 0=no neuronal loss or gliosis; 1=no apparent neuronal loss, but mild gliosis; 2=mild to moderate neuronal loss and moderate gliosis; 3=severe neuronal loss and severe gliosis).

STATISTICAL ANALYSES

The data were analyzed using SPSS 11.5 or 15.0 for Windows (SPSS, Inc, Chicago). The “average” (and “spread”) of data on patient characteristics or ordinal rating scale was estimated by calculating the median (and 25th to 75th percentiles). For group comparison, either the Mann-Whitney *U* test or the Kruskal-Wallis H test were used. Further, the medians and 25th to 75th percentiles of the ratings were calculated from “grouped data” taking into account that one stage follows continuously into the other, and therefore, they represent classes rather than clearly distinguishable values on a numerical scale. When a certain percentile was not available from the grouped data, a standard percentile was obtained. Contingency tables were analyzed with either a χ^2 test (or Fisher exact test) to compare proportions. Association analyses were performed using Spearman rank correlations. The correlation coefficients were interpreted as follows: more than 0.6, strong; between 0.3 and 0.6, moderate; and less than 0.3, weak or negligible correlation. The significance level for all comparisons was set at .01 rather than the usual .05 because multiple statistical tests were done. All statistical tests applied are 2-sided.

RESULTS

PATIENTS' CLINICAL CHARACTERISTICS

We examined 64 subjects including 30 women and 34 men. The patients' characteristics are summarized in

Table 1 and **Table 2**. Seventeen patients (28.3%) had a family history of MND and/or dementia. The disease duration did not differ significantly when comparing the pure ALS with the mixed group (*P* = .61) but was shorter when comparing both of them with the pure FTD group (Table 1) (*P* < .001). Accordingly, age at death was similar in the ALS and mixed groups (*P* = .92) but higher in the FTD group (*P* = .001 and .004, respectively). The most frequent features other than MND or cognitive dysfunction (“plus features”) included extrapyramidal signs, affect disturbances, and depression (Table 2). Whereas 4 mutations and 7 variants in the *PGRN* gene were found by genotyping throughout the whole study cohort (see **Table 3** for the respective diagnostic groups), no mutations or variants in the *TARDBP* gene were detected. No apparent differences in the frequencies of the “plus features” between patients with and without *PGRN* abnormalities were present.

HISTOLOGICAL TDP-43 FINDINGS

A characteristic range of TDP-43 pathology was present differentially in the CNS of various FTLD-U subtypes and these included neuronal and glial cytoplasmic inclusions, neuronal intranuclear inclusions or pathological cellular processes (dystrophic cellular processes or axonal swellings), and diffuse granular cytoplasmic staining (“preinclusions”), as described previously.^{4,6,7}

The cortical pattern of TDP-43- or ubiquitin-positive inclusions as assessed in gray matter of frontotemporal brain areas was consistent with FTLD-U subtype 1, 2, or 3 in 11, 10, and 15 cases, respectively.¹ The remaining 28 cases showed either no or a rare/mild degree of frontotemporal pathology, so the TDP-43 pathology burden here was not sufficient for subtyping (“unclassified group”). Cortical involvement with pathological TDP-43 aggregations was usually accompanied by subcortical white matter TDP-43 pathology that typically was present to a lesser degree and often found in particular in the white matter directly adjacent to the gray matter (ie, cortical-subcortical junction zone).

In all of the disease groups, including both the clinical and pathological categories, evidence of pathological TDP-43 was found in multiple brain areas including the nigrostriatal system and neocortical and allocortical

Table 2. Summary of Clinically Affected Main Domains According to Clinical Diagnosis

Clinical Diagnosis	Percentage										
	Pyramidal Limb Motor Dysfunction				Pyramidal Bulbar Motor Dysfunction				Cognitive Dysfunction		
	Overall	UMN	LMN	Bulbar Onset	Extrapyramidal Signs	Cerebellar Signs	Overall	Frontal Dysfunction ^a	Memory Complaints	Language Impairment	
ALS	100.0	96.2	100.0	80.8	32.0	3.8	0	0	0	0	
Mixed	88.9	82.4	83.3	94.4	38.9	23.5	5.9	100.0	83.3	66.7	
FTD	0	0	0	0		52.6	0	100.0	95.0	78.9	
<i>P</i> value ^b	<.001	<.001	<.001	<.001	.64	<.001	.28	<.001	<.001	<.001	

Clinical Diagnosis	Percentage						
	Affect Disturbances ^c	Other Neuropsychiatric Symptoms ^d	Autonomic Failure	Sensory Complaints	Anxiety	Depression	Others
ALS	7.7	0	7.7	3.8	15.4	13.0	3.8
Mixed	44.4	11.8	0	0	0	29.4	16.7
FTD	15.8	5.3	10.5	0	15.8	42.1	15.8
<i>P</i> value ^b	.02	.11	.56	>.99	.30	.10	.31

Abbreviations: ALS, amyotrophic lateral sclerosis; FTD, frontotemporal dementia; LMN, lower motor neuron; UMN, upper motor neuron.

^aBehavioral, social, dysexecutive.

^b*P* value for any difference: χ^2 test (or Fisher exact test).

^cInappropriate laughing/crying.

^dHallucinations, delusions, agitation, apathy.

Table 3. Patients With Progranulin (*PGRN*) Abnormalities

Clinical Diagnosis	FTLD-U Subtype	cDNA Location of Mutation	Predicted Protein	Pathogenic Mechanism	Variants of Unknown Significance (1, 2)
FTD	3	c.911G>A	p.W304X	Premature termination	c.264 + 7G>A
FTD	3	c.1009C>T	p.Q337X	Premature termination	c.1070C>G, p.P357R c.903G>A, p.S301S
FTD-MND	3	c.1252C>T	p.R418X	Premature termination	
FTD	3	c.1477C>T	p.R493X	Premature termination	
FTD	3				c.708 + 6_708 + 9_delGTGA
FTD-MND	3				c.264 + 7G>A
FTD	1				c.1253G>A, p.R418Q
ALS	Unspecified				c.1297C>T, p.R433W

Abbreviations: ALS, amyotrophic lateral sclerosis; cDNA, complementary DNA; FTD, frontotemporal dementia; FTD-MND, FTD with ALS or motor neuron disease; FTLD-U, frontotemporal lobar degeneration with ubiquitinated inclusions.

brain areas, with varying morphology and degree. The severity of pathology throughout the various groups is depicted in the form of heat maps for cases grouped by subtypes (**Figures 1, 2, 3, and 4**) and by clinical diagnosis (**Figures 5, 6, and 7**). Overall, neocortical pathology was present to a similar high degree throughout FTLD-U subtypes 1 to 3 and to a mild severity in the unclassified group, except for the motor cortex (Figures 1, 2, 3, and 4). Pathology in the motor cortex as a whole was of similar degree in subtypes 1, 2, and 3. Further, the unclassified group showed rare pathology in white matter in nonmotor subcortical areas. There was an increase in the degree of subcortical white matter pathology from subtypes 1 and 2 toward 3 in some brain areas (ie, motor gyrus, midfrontal gyrus, orbitofrontal gyrus, cingulate gyrus, angular gyrus [all *P* values <.01]). The CA4-CA1/subiculum region of the hippocampus showed robust pathology in subtypes 1, 2, and 3 to a similar de-

gree but not in the unclassified group. The striatum or lentiform nuclei were heavily involved throughout subtypes 1 to 3, and to a lesser degree, but still robust, pathology was present in the unclassified group (*P* <.001). Pathology in the substantia nigra was a consistent finding, usually being more pronounced in subtypes 2 and 3 than in subtype 1 and the unclassified subtype (*P* values <.001). Lower motor neurons, including the hypoglossal motor neurons in the medulla and the cervical spinal cord, were most heavily affected in the unclassified group, followed by subtype 2 and subtype 3, and less frequently in subtype 1 (*P* = .002 and <.001, respectively).

Whereas neuronal loss and gliosis were less pronounced than TDP-43 pathology in almost all neocortical brain areas, in the CA4-CA1/subiculum area of the hippocampus and cervical spinal cord, neuron loss and gliosis were present to a similar degree. Further, there was a moderate to strong correlation between (1) neu-

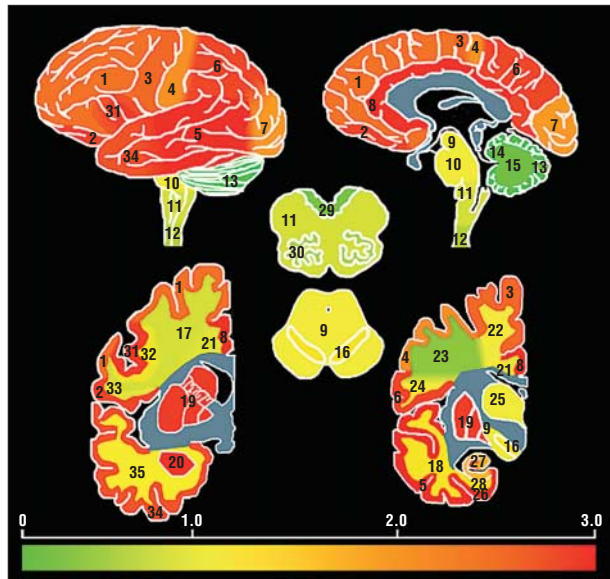


Figure 1. Whole-brain heat map of transactivation response DNA-binding protein with a molecular weight of 43 kDa (TDP-43) pathology in the central nervous system based on the severity of TDP-43 deposits according to the frontotemporal degeneration with ubiquitinated inclusions subtype, which is subtype 1 here. Sagittal, lateral, coronal, and cross sections of central nervous system regions are shown (not every brain area was available for all cases). Colors reflect median scores across all cases calculated from grouped data. The subjacent color scale depicts median scores from zero (green) to highest scores (red) in each region examined, and blue indicates unexamined regions. Numbers identify the following: 1, frontal lobe gray matter; 2, orbital gyrus gray matter; 3, motor gyrus gray matter; 4, sensory gyrus gray matter; 5, temporal lobe gray matter; 6, parietal lobe gray matter; 7, occipital lobe gray matter; 8, cingulate gyrus gray matter; 9, midbrain; 10, pons; 11, medulla; 12, cervical spinal cord; 13, cerebellum gray matter; 14, cerebellum white matter; 15, dentate nucleus in the cerebellum; 16, substantia nigra; 17, frontal lobe white matter; 18, temporal lobe white matter; 19, basal ganglia; 20, amygdala; 21, cingulate gyrus white matter; 22, motor gyrus white matter; 23, sensory gyrus white matter; 24, parietal lobe white matter; 25, thalamus; 26, entorhinal gray matter; 27, hippocampus (CA4-CA1/subiculum and dentate gyrus); 28, entorhinal white matter; 29, medulla dorsal motor plate; 30, medulla inferior olive; 31, Broca area gray matter; 32, Broca area white matter; 33, orbital gyrus white matter; 34, periamygdaloid gray matter; and 35, periamygdaloid white matter.

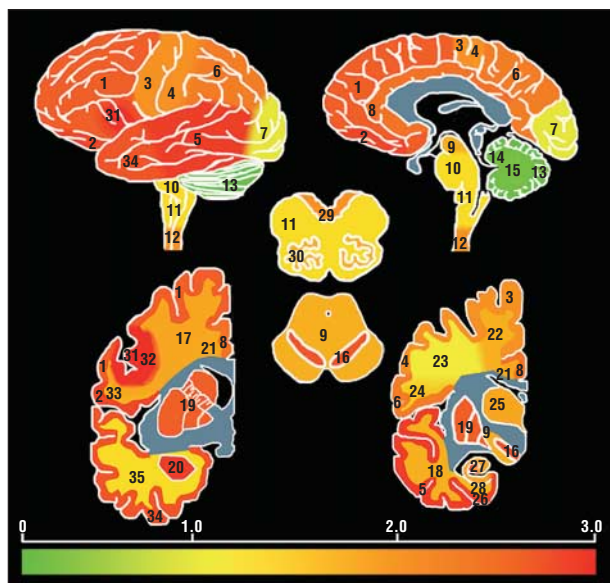


Figure 2. Whole-brain heat map of transactivation response DNA-binding protein with a molecular weight of 43 kDa (TDP-43) pathology in the central nervous system based on the severity of TDP-43 deposits according to the frontotemporal degeneration with ubiquitinated inclusions subtype, which is subtype 2 here. The grading and numbering system are as described in Figure 1.

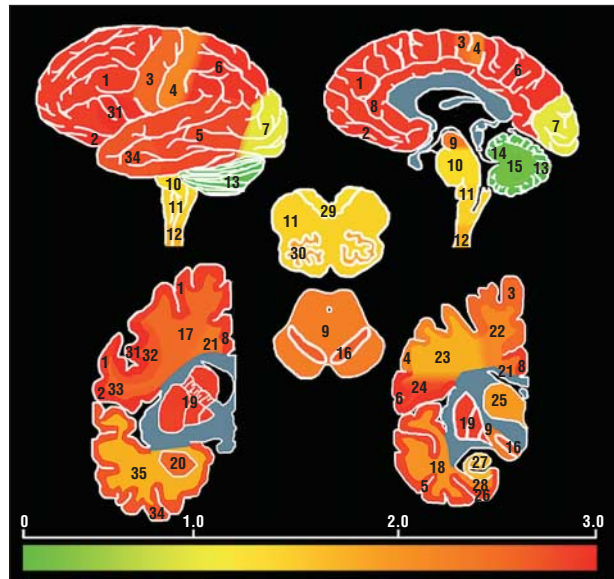


Figure 3. Whole-brain heat map of transactivation response DNA-binding protein with a molecular weight of 43 kDa (TDP-43) pathology in the central nervous system based on the severity of TDP-43 deposits according to the frontotemporal degeneration with ubiquitinated inclusions subtype, which is subtype 3 here. The grading and numbering system are as described in Figure 1.

ronal loss and gliosis and (2) TDP-43 inclusion pathology in most brain areas assessed (**Table 4**). Neurodegeneration was usually accompanied by microglial proliferation based on HLA-DR immunohistochemical staining in the subset of cases assessed to a various degree in a variety of brain areas.

Double-labeling immunofluorescence studies on nigral and other sections showed that Lewy body-like inclusions were TDP-43 and ubiquitin positive but α -synuclein negative. Antiubiquitin antibody stained neuronal TDP-43-positive inclusions on a variety of CNS areas variably, and the TDP-43-positive preinclusions were largely devoid of ubiquitin immunoreactivity while glial TDP-43 inclusions were almost totally ubiquitin negative, as reported previously^{6,7} (data not shown).

CLINICOPATHOLOGICAL CORRELATIONS ACCORDING TO CLINICAL DIAGNOSIS

Throughout the 3 groups solely defined by the clinical syndrome, the frequency of pathology was similar in some brain areas, but not in others, allowing us to delineate 3 overlapping patterns of vulnerability to TDP-43 pathology (Figures 5, 6, and 7). The motor cortex showed robust pathology similarly throughout all clinical diagnostic groups. As to the other cortical brain areas, including midfrontal, temporal, parietal, and periamygdaloid cortex, there were generally significant differences in the severity of pathology between the diagnostic groups, with the ALS group showing the lowest degree of pathology and the mixed and FTD groups being similar ($P < .001$). All but 2 cases in the ALS group showed extramotor neocortical involvement; however, these cases did show TDP-43 pathology in subcortical areas. TDP-43 pathology in the neostriatum or paleostriatum was found in all groups but was present to a higher degree in the mixed

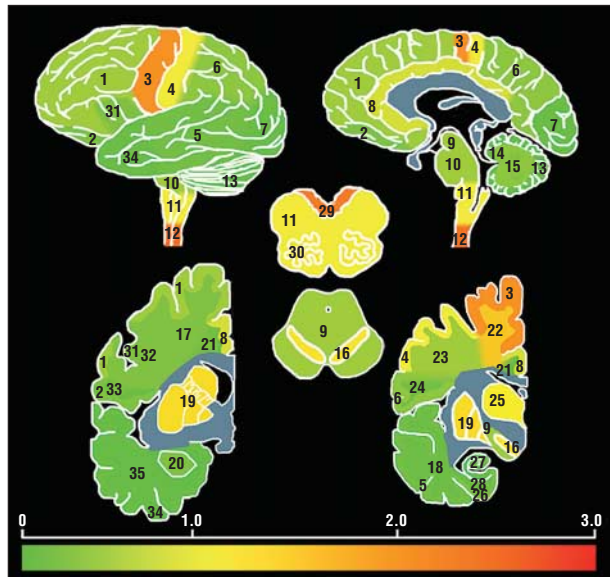


Figure 4. Whole-brain heat map of transactivation response DNA-binding protein with a molecular weight of 43 kDa (TDP-43) pathology in the central nervous system based on the severity of TDP-43 deposits according to the frontotemporal degeneration with ubiquitinated inclusions (FTLD-U) subtype, which is FTLD-U unclassified as described in the text. The grading and numbering system are as described in Figure 1.

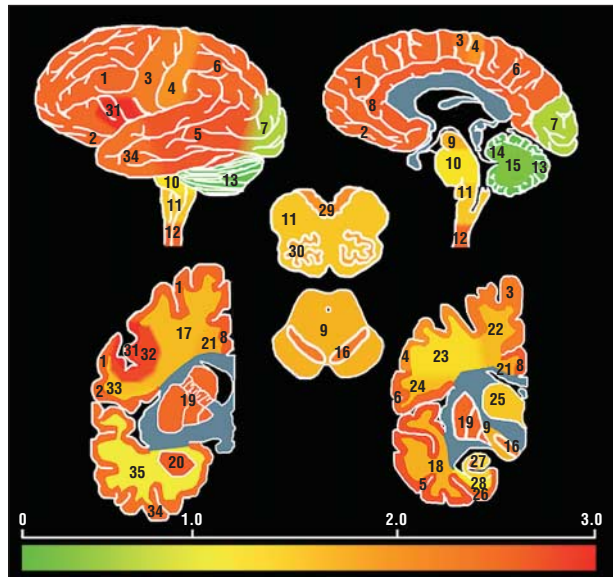


Figure 6. Whole-brain heat map of transactivation response DNA-binding protein with a molecular weight of 43 kDa (TDP-43) pathology in the central nervous system based on the severity of TDP-43 deposits according to the clinical diagnosis, which is mixed frontotemporal dementia and motor neuron disease here. The grading and numbering system are as described in Figure 1.

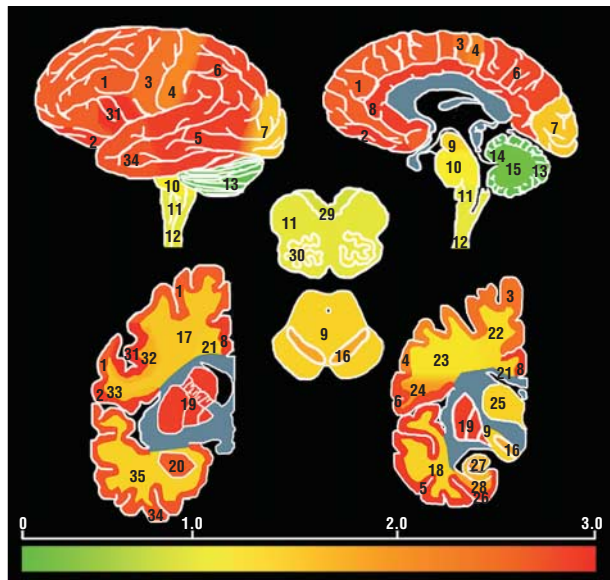


Figure 5. Whole-brain heat map of transactivation response DNA-binding protein with a molecular weight of 43 kDa (TDP-43) pathology in the central nervous system based on the severity of TDP-43 deposits according to the clinical diagnosis, which is frontotemporal dementia here. The grading and numbering system are as described in Figure 1.

and FTD groups as compared with the pure ALS group ($P < .001$). Conversely, lower motor neurons were heavily affected by TDP-43 pathology in the ALS or mixed group but less in the FTD group ($P < .001$). However, 12 of 16 cases in the FTD group showed an overall mild degree of lower motor neuron pathology. The motor cortex of the FTD group was affected in all 18 individuals examined, although to a different degree and reflecting the morphological distribution of each histological subtype. Of these, 7 patients were found to show cytoplasmic inclu-

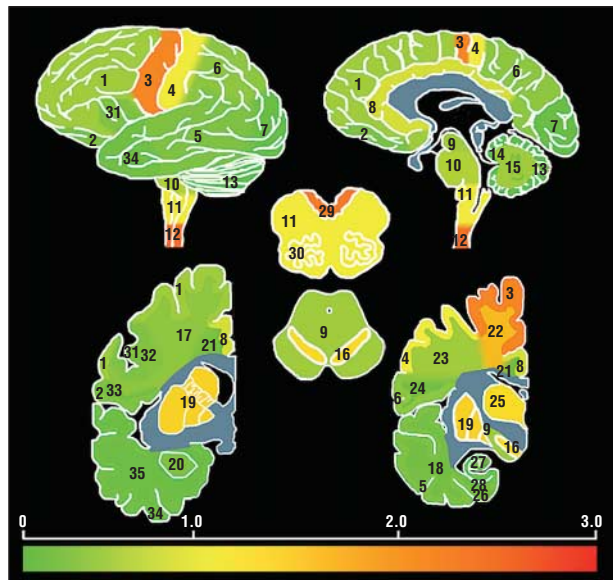


Figure 7. Whole-brain heat map of transactivation response DNA-binding protein with a molecular weight of 43 kDa (TDP-43) pathology in the central nervous system based on the severity of TDP-43 deposits according to the clinical diagnosis, which is amyotrophic lateral sclerosis here. The grading and numbering system are as described in Figure 1. This Figure is similar to Figure 1B in Geser et al,⁶ but cases with dementia have been excluded, a new amyotrophic lateral sclerosis case has been included, and the color code has been modified.

sion pathology in the Betz cells, including both “preinclusions” and “mature” skeinlike or more compact aggregations. Although corresponding to their clinical classification as FTD, these patients did not display any upper motor neuron signs. When including the whole study cohort and the full thickness of the motor cortex, there were no significant differences in the degree of TDP-43 pathology or gliosis in patients with or without

Table 4. Neuronal Loss and Gliosis (NL&GL) Compared and Correlated With TDP-43 Inclusion Pathology Throughout Whole Study Population

	Median (IQR) ^a						
	MCtxx	MFCtx	OFCtx	BCtx	SCtx	ACtx	CCtx
TDP-43	2.2 (1.4-2.8)	1.7 (0.5-2.7)	1.7 (0.3-2.8)	2.7 (2.0-3.0 ^b)	1.8 (1.2-2.5)	1.6 (0.4-2.8)	2.0 (0.8-2.9)
NL&GL	1.0 (0.4-1.7)	0.8 (0.2-1.6)	0.6 (0.0-1.4)	1.3 (0.4-2.7)	0.6 (0.1-1.3)	0.6 (0.0-1.4)	0.8 (0.1-1.8)
<i>P</i> value ^c	<.001	<.001	<.001	.10	.001	<.001	<.001
<i>r</i> ^d	0.242 ^e	0.674 ^f	0.697 ^f	0.829 ^g	0.559 ^e	0.642 ^f	0.579 ^f
	PACtx	TCtx	ERCtx	CA1-CA4/S	OCtx	CSC	
TDP-43	1.3 (0.2-2.7)	2.0 (0.3-2.9)	1.9 (0.4-2.9)	0.9 (0.2-1.8)	0.6 (0.0-1.4)	1.9 (1.1-2.7)	
NL&GL	0.6 (0.0 ^b -1.7)	0.9 (0.2-1.9)	0.7 (0.0-1.7)	0.8 (0.1-1.9)	0.2 (0.0 ^b -0.7)	1.6 (0.7-2.6)	
<i>P</i> value ^c	.001	<.001	<.001	.84	<.001	.57	
<i>r</i> ^d	0.600 ^f	0.726 ^f	0.667 ^f	0.515 ^f	0.354 ^g	0.470 ^g	

Abbreviations: ACtx, angular cortex; BCtx, Broca area cortex; CA1-CA4/S, CA4-CA1/subiculum of the hippocampus; CCtx, cingulate cortex; CSC, cervical spinal cord; ERCtx, entorhinal cortex; IQR, interquartile range; MCtx, motor cortex; MFCtx, midfrontal cortex; OCtx, occipital cortex; OFCtx, orbitofrontal cortex; PACtx, periamygdaloid cortex; SCtx, sensory cortex; TCtx, temporal cortex; TDP-43, transactivation response DNA-binding protein with a molecular weight of 43 kDa.

^a Calculated from grouped data (except^b).

^b Not calculated from grouped data.

^c Wilcoxon signed rank test, compares degree of TDP-43 pathology with degree of NL&GL.

^d Spearman correlation coefficient, correlates degree of TDP-43 pathology with degree of NL&GL.

^e Not significant.

^f *P* < .001.

^g *P* < .01.

clinical evidence of upper motor neuron signs. Pathology in the frontal gyrus was more severe in patients with clinical symptoms or signs consistent with frontal dysfunction, namely behavioral or social deficits and dys-executive symptoms (*P* < .001). There was also a significant difference in the cortical and subcortical white matter pathology degree in the temporal cortex (including the Wernicke area) and the angular cortex between the patients with and without language dysfunction (*P* < .001). When comparing the degree of both TDP-43 pathology and neuronal loss associated with gliosis in the hippocampal formation, including the CA4-CA1/subiculum and dentate gyrus throughout the whole study cohort, patients with memory complaints showed a highly significant greater degree of TDP-43 pathology and neuron loss as compared with patients without (*P* < .001). Further, there was a trend toward a higher degree of TDP-43 pathology in the amygdala in patients with affect disturbances as compared with those without in the whole study cohort (*P* = .03). Moreover, there was a difference in the severity of TDP-43 pathology in the striatum, but not in the substantia nigra, when comparing subjects with and without extrapyramidal symptoms (*P* = .01 and *P* = .12, respectively).

CLINICOPATHOLOGICAL CORRELATION ACCORDING TO FTLD-U SUBTYPES

The disease duration was significantly lower when comparing the unclassifiable group with FTLD-U subtype 1 (*P* < .001), with the subtypes 2 and 3 having intermediate disease duration (Table 5). The unclassifiable group had significantly higher brain weights as compared with the subtypes 1 through 3 (all *P* < .001). The clinical features according to FTLD-U subtyping are depicted in Table 6. All mutations (n=4) and 5 variants in PGRN

were present in the FTLD-U subtype 3 group, and 1 variant each was found in the FTLD-U subtype 1 and unclassified subtype groups. A breakdown of the frequencies of the morphological subtypes according to the clinical diagnoses is depicted in Table 7. Only 2 ALS cases were classifiable according to FTLD-U subtypes and they showed subtype 2 morphology. The mixed group exhibited similar proportions of subtypes 2 and 3 TDP-43 pathology (two-thirds each or more) but fewer unclassifiable cases (less than a quarter). The vast majority of subtype 1 cases were found in the pure FTD group. Further, subtypes 1 and 3 TDP-43 distribution patterns of pathology were present in 40% to 50% of patients in this group, and subtype 2 was rare (10%).

COMMENT

Since pathological TDP-43 has been recognized as playing a major role in human diseases that had long been acknowledged as being associated with ubiquitin-positive but tau- and α-synuclein-negative inclusions,⁴ there is an increasing number of publications on the presence of this alteration in a variety of neurodegenerative diseases. In fact, pathological TDP-43 has been shown to be either the main diagnosis-defining finding or to be present as an additional pathology in diseases determined by aggregation of other altered proteins such as tau or α-synuclein.⁹ However, these studies are heterogeneous in their designs and definite clinicopathological conclusions are difficult to draw at this time. Based on the "clinicopathological spectrum idea,"⁹ the present study was set to delineate the major TDP-43 diseases, covering anatomically and functionally salient brain and spinal cord areas, to eventually establish the whole-CNS pattern of TDP-43 pathology for different pathological subtypes and for the clinical phenotypes studied herein.

Table 5. Summary of Patient Characteristics According to FTLD-U Subtype

Subtype	Sample Size	Male:Female Ratio	Family History, %	Median (IQR)		PGRN Genotyping Status	Median (IQR)	
				Age at Death, y	Disease Duration, y		PMI, h	Brain Weight, g
Type 1	11	1:0.8	25.0	72.5 (65.5-77.0)	7.7 (5.3-10.8)	0 mutations; 1 variant	10.8 (7.0-17.0)	1084.0 (1004.8-1246.5)
Type 2	10	1:0.7	40.0	62.5 (56.0-69.0)	3.5 (1.6-6.7)	0 mutations; 0 variant	12.0 (8.0-21.7)	1200.0 (1130.0-1297.0)
Type 3	15	1:2	57.1	63.5 (53.7-75.0)	4.0 (1.9-6.8)	5 mutations; 4 variants	11.5 (6.5-19.0)	1160.0 (936.8-1294.5)
Type unclassified	28	1:0.6	10.7	58.3 (53.3-64.7)	2.3 (1.4-3.3)	1 variant	14.0 (8.8-17.6)	1419.5 (1291.5-1533.0)
P value		.37 ^a	.001 ^a	.02 ^b	.002 ^b		.90 ^b	<.001 ^b

Abbreviations: FTLD-U, frontotemporal lobar degeneration with ubiquitinated inclusions; IQR, interquartile range; PMI, postmortem interval.

^a P value for any difference: χ^2 test.

^b P value for any difference: Kruskal-Wallis H test.

Table 6. Summary of Clinically Affected Main Domains According to FTLD-U Subtype

Subtype	Percentage										
	Pyramidal Limb Motor Dysfunction			Pyramidal Bulbar Motor Dysfunction	Bulbar Onset	Extrapyramidal Signs	Cerebellar Signs	Cognitive Dysfunction			
	Overall	UMN	LMN					Overall	Frontal Dysfunction ^a	Memory Complaints	Language Impairment
Type 1	0	0	0	9.1	100.0	36.4	0	100.0	90.9	81.8	100.0
Type 2	80.0	70.0	80.0	70.0	25.0	50.0	10.0	80.0	80.0	70.0	50.0
Type 3	42.9	38.5	35.7	50.0	28.6	38.5	0	100.0	93.3	64.3	76.9
Type unclassified	100.0	96.4	100.0	82.1	37.0	3.6	0	14.3	7.1	7.1	7.1
P value ^b	<.001	<.001	<.001	<.001	.506	.007	.16	<.001	<.001	<.001	<.001

Subtype	Percentage						
	Affect Disturbances ^c	Other Neuropsychiatric Symptoms ^d	Autonomic Failure	Sensory Complaints	Anxiety	Depression	Others
Type 1	9.1	0	0	0	9.1	45.5	18.2
Type 2	30.0	20.0	0	0	10.0	30.0	20.0
Type 3	35.7	7.7	15.4	0	8.3	38.5	7.7
Type unclassified	14.3	0	7.1	3.6	14.3	12.0	7.1
P value ^b	.26	.07	.37	.75	.94	.14	.57

Abbreviations: FTLD-U, frontotemporal lobar degeneration with ubiquitinated inclusions; LMN, lower motor neuron; UMN, upper motor neuron.

^a Behavioral, social, dysexecutive.

^b P value for any difference: Kruskal-Wallis H test.

^c Inappropriate laughing/crying.

^d Hallucinations, delusions, agitation.

Frontotemporal lobar degeneration with ubiquitinated inclusions has long been recognized as being a primarily cortical disease with pathology being located in frontal and temporal brain areas. We herein show that the clinical syndrome of FTD with and without MND is associated with TDP-43 pathology accompanied by various degrees of neuronal loss and gliosis throughout the whole CNS, with no areas as examined being entirely spared. Although “frontotemporal degeneration” has been used in the past as the “defining criterion” for FTLD, these brain areas do not stand out in their pathology as compared with other cortical brain areas. In fact, the degree of pathology in most neocortical brain areas is very similar. Subcortical degeneration, such as pathology in the basal ganglia or amygdala, is usually present to a similar degree as in cortical regions, thereby suggesting that FTLD-U is not primarily a cortical degeneration as im-

plied by its designation. All the clinical groups, including FTD with and without MND and ALS, showed widespread CNS TDP-43 pathology; however, the presence of ALS was associated with a higher burden of inclusions in lower motor neuron nuclei. Likewise, the presence or absence of cognitive dysfunction was associated with the degree of cortical TDP-43 pathology.

Group comparison of salient clinical domains, including cognitive and motor features, as to the severity of neurodegeneration showed a higher degree of pathology in their functionally related brain areas. Betz cells and anterior horn cells were affected to an overall mild degree in the FTD group relative to the ALS group, and mild pathology in cortical brain areas was present in the ALS group relative to the FTD group. These findings corroborate the concept of a clinicopathological spectrum of TDP-43 pathology extending from FTLD at one end

Table 7. FTLD-U Type Classification Across Clinical Diagnosis^a

Clinical Diagnosis	Pathological Diagnosis, FTLD-U Subtype, No. (%) ^b			
	Type 1	Type 2	Type 3	Type Unclassified
ALS	0	2 (7.7)	0	24 (92.3)
Mixed	1 (5.6)	6 (33.3)	7 (38.9)	4 (22.2)
FTD	10 (50.0)	2 (10.0)	8 (40.0)	0

Abbreviations: ALS, amyotrophic lateral sclerosis; FTD, frontotemporal dementia; FTLD-U, frontotemporal lobar degeneration with ubiquitinated inclusions.

^a $P < .001$ (Fisher exact test).

^b Numbers are counts, and percentages are proportions of subtype of clinical diagnosis.

and ALS at the other. Whenever MND was clinically present, either as pure ALS or ALS-FTD, both disease duration and age at death were shorter as compared with the pure FTD group, indicating that the involvement of the motor neuron system is associated with a more aggressive disease course as compared with other dementing illnesses. Conversely, the brain weight was lowest in the FTD group and highest in the ALS group, with intermediate values for the mixed cases, indicating that an extended disease period allows for the development of neurodegeneration and related CNS atrophy. Besides the defining clinical syndromes in the voluntary motor and cognitive domain, extrapyramidal signs were the most common feature. These were significantly more frequent whenever dementia was clinically present and are consistent with the robust pathology found in the striatum. Affect disturbances were common as well and appeared to be associated with severe pathology in the amygdala. Also, depression was frequently encountered, although the exact neuroanatomical site of pathology in the brain is less established. Anxiety or other neuropsychiatric symptoms were occasionally reported. Other features, such as autonomic failure, sensory complaints, or cerebellar signs, were rare.

However, there are possible limitations of the present study because of the retrospective nature of the acquisition of the clinical data. Additional features other than the defining syndromes of dementia or MND might have been present but not evaluated or recorded or they might have been clinically masked by the predominating clinical features. Thus, the frequencies of various clinical signs and symptoms as reported herein should be regarded as “conservative” estimates. On the other hand, we were especially interested in detecting early clinical manifestations of underlying pathology, and this might have increased the representation of some features, such as the high frequency of memory problems in our FTD group, since both patients’ complaints and physician-assessed signs (when available) were considered. Similarly, any extrapyramidal sign, even when isolated, was recorded. Unfortunately, detailed neuropsychological or motor performance assessments were not available for many cases and thus were not included in the analysis.

We herein show that all FTLD-U subtypes are associated with whole-CNS pathology, although there are regional differences in the pathology burden between the subtypes. The finding that all but 2 cases in the ALS group showed extramotor cortical TDP-43 pathology, which was usually present to a rare to mild degree, points toward a subclinical or preclinical involvement of wide cortical areas, such as the association cortex, in a disease still clinically restricted to motor neuron symptoms. Accordingly, in 2 cases, the neocortex involvement was sufficient for a diagnosis of FTLD-U subtype 2. The finding of the white matter TDP-43 pathology being present in particular directly adjacent to the affected cortex points toward an involvement of subcortical U fibers. Subtype 1 was associated with less subcortical gray and white matter pathology and less lower motor neuron pathology as compared with subtypes 2 and 3. Also, all but one of the subtype 1 cases were allocated to the clinically pure FTD group. Taken together with the findings of the lower brain weight and highest disease duration or age at death in patients with subtype 1, this suggests that FTLD-U subtype 1 represents the most “cortical variant of degeneration” in comparison with subtypes 2 and 3, although subcortical pathology, in particular in the basal ganglia, is present as well, consistent with the continuous multisystem idea of all these diseases. Subtypes 2 and 3 are more similar and closer to the motor neuron disease phenotype when compared with subtype 1. Similarly, it has been published that patients with FTLD-U with numerous neuronal cytoplasmic inclusions, as occurring in FTLD-U subtype 2 or 3, have shorter survival than those with subtype 1.¹⁴ Further, it has been reported that cases with predominantly neuronal intracytoplasmic inclusions correspond to FTD-MND clinically, whereas cases with predominantly dystrophic neurites show semantic dementia, and when neuronal cytoplasmic inclusions and dystrophic neurites are coupled with neuronal intranuclear inclusions, progressive nonfluent aphasia is present.³ The whole-CNS map of pathology of the unclassified subtype is very similar to the ALS whole-CNS map, given that the degree of frontotemporal cortical pathology was used for subtyping.

The finding of *PGRN* gene mutations being restricted to FTLD-U subtype 3 cases is consistent with the literature,² as is the presence of a *PGRN* variant in our ALS group.¹⁵ The lack of apparent clinical or neuropathological differences between cases with and without *PGRN* gene abnormalities that we report herein is consistent with a recent study showing a distinct phenotype being present only at the molecular level.¹⁶ Our finding that not all cases with a family history of dementia and/or MND throughout all clinical or pathological groups were demonstrated to have *PGRN* or *TARDBP* gene mutations as tested suggests a role for other genetic abnormalities, such as mutations in chromosome 9p or other, as yet unidentified, genetic loci.^{2,17}

In conclusion, we herein show that there is a widespread distribution of pathological TDP-43 throughout all clinical and pathologically defined groups establishing a whole-CNS disease. The idea of a predominantly frontotemporal degeneration pattern in FTLD-U and a primarily pyramidal tract degeneration pattern in MND should be refined in favor of a broad clinicopathological spectrum disease involving multiple systems with dif-

ferences in the distribution of pathology and clinical symptoms being present, at least, at group level. In a given case, however, a clear allocation into one of the groups might be difficult or even impossible because of the significant overlap of the clinical and pathological features and associated diagnostic terms. These data support the conclusions of a number of recent reports⁹ on pathological TDP-43 that FTD and ALS linked to TDP-43 pathology represent a single multiple-system disease, designated as TDP-43 multisystem proteinopathy.

Accepted for Publication: October 1, 2008.

Author Affiliations: Center for Neurodegenerative Disease Research, Department of Pathology and Laboratory Medicine, Alzheimer's Disease Core Center, Institute on Aging (Drs Geser, Martinez-Lage, Uryu, Kwong, Van Deerlin, Lee, and Trojanowski and Messrs Robinson, Brandmeir, and Malunda), and Departments of Biostatistics and Epidemiology (Dr Xie) and Neurology (Drs Elman, McCluskey, Clark, and Grossman), University of Pennsylvania School of Medicine, Philadelphia; Department of Neurology, Hospital de la Santa Creu i Sant Pau, Autonomous University of Barcelona, Barcelona, Spain (Dr Martinez-Lage); Center for Neuropathology and Prion Research, Ludwig-Maximilians University, Munich, Germany (Dr Neumann); Alzheimer's Disease Center, Albany Medical Center (Dr Zimmerman and Mr Brandmeir), and Department of Pathology and Laboratory Medicine, Albany Medical College (Dr Qian), Albany, New York; and Department of Neurology, University of California at San Francisco (Dr Miller).

Correspondence: John Q. Trojanowski, MD, PhD, Department of Pathology and Laboratory Medicine, University of Pennsylvania School of Medicine, HUP, Maloney 3rd Floor, 36th and Spruce Streets, Philadelphia, PA 19104-4283 (trojanow@mail.med.upenn.edu).

Author Contributions: Dr Trojanowski had full access to all of the data in the study and takes responsibility for the integrity of the data and the accuracy of the data analysis. *Study concept and design:* Geser, Martinez-Lage, Neumann, and Kwong. *Acquisition of data:* Geser, Martinez-Lage, Robinson, Uryu, Neumann, Brandmeir, Elman, McCluskey, Clark, Malunda, Miller, Zimmerman, Qian, Van Deerlin, and Grossman. *Analysis and interpretation of data:* Geser, Martinez-Lage, Robinson, Uryu, Brandmeir, Xie, McCluskey, Van Deerlin, Grossman, Lee, and Trojanowski. *Drafting of the manuscript:* Geser, Martinez-Lage, Uryu, Malunda, and Grossman. *Critical revision of the manuscript for important intellectual content:* Geser, Martinez-Lage, Robinson, Neumann, Brandmeir, Xie, Kwong, Elman, McCluskey, Clark, Miller, Zimmerman, Qian, Van Deerlin, Grossman, Lee, and Trojanowski. *Statistical analysis:* Geser, Xie, and Grossman. *Obtained funding:* Miller and Van Deerlin. *Administrative, technical, and material support:* Robinson, Uryu, Brandmeir, Kwong, McCluskey, Malunda, Miller, Zimmerman, Qian, Van Deerlin, and Lee. *Study supervision:* Trojanowski.

Financial Disclosure: None reported.

Funding/Support: This work was funded by grants AG10124, AG17586, and HL071483 from the National Institutes of Health.

Additional Information: Drs Geser and Martinez-Lage contributed equally to this article. The eTable is available at <http://www.archophthalmol.com>.

Additional Contributions: Theresa Schuck, BA, Sungmi Jung, MD, Monica Getahun, BS, and Natascha Gownaris provided expert technical assistance. We thank the patients and families who made this research possible.

REFERENCES

1. Sampathu DM, Neumann M, Kwong LK, et al. Pathological heterogeneity of frontotemporal lobar degeneration with ubiquitin-positive inclusions delineated by ubiquitin immunohistochemistry and novel monoclonal antibodies. *Am J Pathol*. 2006;169(4):1343-1352.
2. Cairns NJ, Bigio EH, Mackenzie IR, et al; Consortium for Frontotemporal Lobar Degeneration. Neuropathologic diagnostic and nosologic criteria for frontotemporal lobar degeneration: consensus of the Consortium for Frontotemporal Lobar Degeneration. *Acta Neuropathol*. 2007;114(1):5-22.
3. Mackenzie IR, Baborie A, Pickering-Brown S, et al. Heterogeneity of ubiquitin pathology in frontotemporal lobar degeneration: classification and relation to clinical phenotype. *Acta Neuropathol*. 2006;112(5):539-549.
4. Neumann M, Sampathu DM, Kwong LK, et al. Ubiquitinated TDP-43 in frontotemporal lobar degeneration and amyotrophic lateral sclerosis. *Science*. 2006;314(5796):130-133.
5. Brooks BR, Miller RG, Swash M, Munsat TL; World Federation of Neurology Research Group on Motor Neuron Diseases. El Escorial revisited: revised criteria for the diagnosis of amyotrophic lateral sclerosis. *Amyotroph Lateral Scler Other Motor Neuron Disord*. 2000;1(5):293-299.
6. Geser F, Brandmeir NJ, Kwong LK, et al. Evidence of multisystem disorder in whole-brain map of pathological TDP-43 in amyotrophic lateral sclerosis. *Arch Neurol*. 2008;65(5):636-641.
7. Brandmeir NJ, Geser F, Kwong LK, et al. Severe subcortical TDP-43 pathology in sporadic frontotemporal lobar degeneration with motor neuron disease. *Acta Neuropathol*. 2008;115(1):123-131.
8. Nishihira Y, Tan CF, Onodera O, et al. Sporadic amyotrophic lateral sclerosis: two pathological patterns shown by analysis of distribution of TDP-43-immunoreactive neuronal and glial cytoplasmic inclusions. *Acta Neuropathol*. 2008;116(2):169-182.
9. Kwong LK, Uryu K, Trojanowski JQ, Lee VM. TDP-43 proteinopathies: neurodegenerative protein misfolding diseases without amyloidosis. *Neurosignals*. 2008;16(1):41-51.
10. Davidson Y, Kelley T, Mackenzie IR, et al. Ubiquitinated pathological lesions in frontotemporal lobar degeneration contain the TAR DNA-binding protein, TDP-43. *Acta Neuropathol*. 2007;113(5):521-533.
11. Bigio EH. Update on recent molecular and genetic advances in frontotemporal lobar degeneration. *J Neuropathol Exp Neurol*. 2008;67(7):635-648.
12. Neary D, Snowden JS, Gustafson L, et al. Frontotemporal lobar degeneration: a consensus on clinical diagnostic criteria. *Neurology*. 1998;51(6):1546-1554.
13. Mackenzie IR, Feldman HH. Ubiquitin immunohistochemistry suggests classic motor neuron disease, motor neuron disease with dementia, and frontotemporal dementia of the motor neuron disease type represent a clinicopathologic spectrum. *J Neuropathol Exp Neurol*. 2005;64(8):730-739.
14. Grossman M, Wood EM, Moore P, et al. TDP-43 pathologic lesions and clinical phenotype in frontotemporal lobar degeneration with ubiquitin-positive inclusions. *Arch Neurol*. 2007;64(10):1449-1454.
15. Sleegers K, Brouwers N, Maurer-Stroh S, et al. Progranulin genetic variability contributes to amyotrophic lateral sclerosis. *Neurology*. 2008;71(4):253-259.
16. Chen-Plotkin AS, Geser F, Plotkin JB, et al. Variations in the progranulin gene affect global gene expression in frontotemporal lobar degeneration. *Hum Mol Genet*. 2008;17(10):1349-1362.
17. Morita M, Al Chalabi A, Andersen PM, et al. A locus on chromosome 9p confers susceptibility to ALS and frontotemporal dementia. *Neurology*. 2006;66(6):839-844.