



Inclusion body myositis: old and new concepts

A A Amato and R J Barohn

J. Neurol. Neurosurg. Psychiatry 2009;80;1186-1193
doi:10.1136/jnnp.2009.173823

Updated information and services can be found at:
<http://jnnp.bmj.com/cgi/content/full/80/11/1186>

These include:

References

This article cites 97 articles, 31 of which can be accessed free at:
<http://jnnp.bmj.com/cgi/content/full/80/11/1186#BIBL>

Rapid responses

You can respond to this article at:
<http://jnnp.bmj.com/cgi/eletter-submit/80/11/1186>

Email alerting service

Receive free email alerts when new articles cite this article - sign up in the box at the top right corner of the article

Topic collections

Articles on similar topics can be found in the following collections

[Muscle disease](#) (1299 articles)
[Neuromuscular disease](#) (8274 articles)
[Musculoskeletal syndromes](#) (16537 articles)
[Surgical diagnostic tests](#) (6051 articles)
[Immunology \(including allergy\)](#) (43293 articles)
[Radiology](#) (14608 articles)

Notes

To order reprints of this article go to:
<http://journals.bmj.com/cgi/reprintform>

To subscribe to *Journal of Neurology, Neurosurgery, and Psychiatry* go to:
<http://journals.bmj.com/subscriptions/>

Inclusion body myositis: old and new concepts

A A Amato,¹ R J Barohn²

¹ Department of Neurology, Brigham and Women's Hospital, Harvard Medical School, Boston, Massachusetts, USA;

² Department of Neurology, University of Kansas Medical Center, Kansas City, Kansas, USA

Correspondence to:
Dr A A Amato, Department of Neurology, Brigham and Women's Hospital, 75 Francis St, Boston, MA 02115, USA; aamato@partners.org

Received 27 January 2009
Accepted 15 April 2009

ABSTRACT

Inclusion body myositis (IBM) is the most common idiopathic inflammatory myopathy occurring in patients over the age of 50 years and probably accounts for about 30% of all inflammatory myopathies. Muscle biopsy characteristically reveals endomysial inflammation, small groups of atrophic fibres, eosinophilic cytoplasmic inclusions and muscle fibres with one or more rimmed vacuoles. However, any given biopsy may lack these histopathological abnormalities; the clinical examination is often the key to diagnosis. Early and often asymmetrical weakness and atrophy of the quadriceps and flexor forearm muscles (ie, wrist and finger flexors) are the clinical hallmarks of IBM. The pathogenesis of IBM is unknown. It may be autoimmune inflammatory myopathy or a primary degenerative myopathy with a secondary inflammatory. A prevailing theory is that there is an overproduction of β -amyloid precursor protein in muscle fibres that is somehow cleaved into abnormal β -amyloid, and the accumulation of the latter is somehow toxic to muscle fibres. However, there are many problems with this theory and more work needs to be done. Unfortunately, IBM is generally refractory to therapy. Further research into the pathogenesis, along with both preliminary small pilot trials and larger double blind, placebo controlled efficacy trials, are needed to make progress in our understanding and therapeutic approach for this disorder.

Inclusion body myositis (IBM) is one of the four major idiopathic inflammatory myopathies, along with dermatomyositis (DM), polymyositis (PM), and immune mediated necrotising myopathy (NM). These four disorders are clinically, histologically, and pathogenetically distinct.¹⁻⁵ IBM is the most common idiopathic inflammatory myopathy occurring in patients over the age of 50 years and probably accounts for about 30% of all inflammatory myopathies.²⁻⁶⁻⁸ IBM is the most common or a close second to sarcopenia as the most common myopathy in the elderly. Frequently, the diagnosis of IBM is delayed and initial errors in diagnosis are common. Accurate diagnosis is important because IBM is the least likely of the four idiopathic inflammatory myopathies to improve with immunosuppressive therapy.⁹

IBM is sporadic in nature. There are a few reports of IBM occurring in parents, children and in siblings of affected patients, suggesting a possible genetic predisposition to developing IBM, possibly secondary to inherited human leucocyte antigen haplotypes. There are hereditary forms of inclusion body *myopathy*, but with rare exceptions, the muscle biopsies in these cases lack inflammation and the clinical phenotype (ie, age of onset, pattern of weakness) is different from sporadic inclusion body *myositis* (IBM).¹⁰

Most published papers regarding epidemiology of the inflammatory myopathies have used Bohan and Peter criteria.¹¹⁻¹³ However, these criteria were developed before IBM was widely recognised and cases of IBM would have been misdiagnosed as PM with Bohan and Peter criteria.¹⁴⁻¹⁵ Revised criteria for the various idiopathic inflammatory myopathies have been devised to take into account the recent advancements in the field.¹⁰⁻¹⁶ In the Netherlands, the prevalence was established to be 4.9 IBM patients per million inhabitants.¹⁷ A similar estimated prevalence exists in Sweden (3.3 per million) with an incidence of 2.2 per million per year.¹⁸

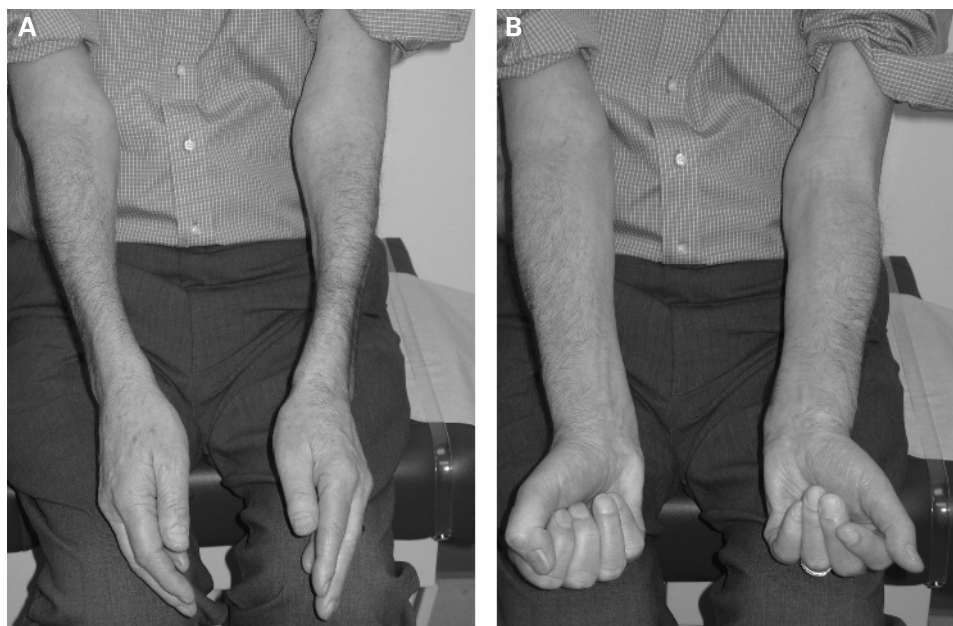
CLINICAL FEATURES

IBM is characterised clinically by the insidious onset of slowly progressive proximal and distal weakness which generally develops after the age of 50 years.¹⁻³⁻⁶⁻⁸⁻¹⁰⁻¹⁸⁻²¹ Diagnosis of IBM is often not made until 5-8 years after the onset of symptoms. The slow evolution of the disease may in part account for the delay in diagnosis. Men are much more commonly affected than women. In contrast, there is a female predominance in DM and PM.

Early weakness and atrophy of the quadriceps and forearm flexor muscles (ie, wrist and finger flexors) (fig 1) are the clinical hallmarks of IBM.¹⁻³⁻⁶⁻⁸⁻¹⁰⁻¹⁸⁻²⁰⁻²¹ Ankle dorsiflexors are also often involved at early stages. In approximately two-thirds of patients, we find on manual muscle testing that the MRC grades of the finger and wrist flexors (in particular the deep finger flexors) are lower than those of the shoulder abductors, and the muscle scores of the knee extensors and ankle dorsiflexor are the same as or lower than those of the hip flexors.² In contrast, the proximal muscles (shoulder abductors and hip flexors) are usually weaker than the distal muscle groups by manual muscle testing grades in DM, PM and NM. In a recently published study of 57 patients with IBM in Australia, the initial symptoms in the majority of cases were attributable to quadriceps weakness (79%), finger weakness (12%), foot drop (7%) or dysphagia (1.8%).²¹ Asymmetric involvement was common (82%), particularly of the forearm muscles, with the non-dominant side being more severely affected in most cases. This contrasts with the symmetrical involvement typically seen in DM, PM and NM.

Dysphagia occurs in at least 40% of patients due to oesophageal and pharyngeal muscle involvement. This can lead to weight loss or aspiration. In severe cases, cricopharyngeal myotomy may be beneficial.⁶⁻²²⁻²³ Mild facial weakness is evident in one-third of cases.²⁻⁶ Although sensory symptoms are usually lacking, as many as 30% have evidence of a generalised sensory peripheral neuropathy on

Figure 1 Note the atrophy of both forearms, particular the ventral aspects (A) and the asymmetrical weakness of finger flexion (B).



clinical examination and electrophysiological testing.² Muscle stretch reflexes are normal or slightly decreased. In particular, the patellar reflexes are lost early.

As many as 15% of IBM patients have underlying autoimmune disorders such as systemic lupus erythematosus, Sjogren syndrome, scleroderma, sarcoidosis, variable immunoglobulin deficiency or thrombocytopenia.^{24 25} However, unlike DM and PM, IBM is not associated with myocarditis, lung disease or an increased risk of malignancy.

LABORATORY FEATURES

Serum creatine kinase (CK) is normal or only mildly elevated (usually less than 10-fold above normal).^{2 6 10} Some have reported positive antinuclear antibodies in approximately 20% of their IBM patients but so-called myositis specific antibodies are usually absent.²⁵⁻²⁷ Approximately 20% of patients may have a small monoclonal gammopathy of undetermined significance. There is a significant incidence of the human leucocyte antigen DR3 phenotype (*0301/0302) in IBM.²⁸ Skeletal muscle MRI scans demonstrate atrophy and signal abnormalities in affected muscle groups.^{29 30}

ELECTROPHYSIOLOGICAL STUDIES

Up to 30% of patients on nerve conduction studies have evidence of a mild axonal sensory neuropathy.² EMG demonstrates increased spontaneous and insertional activity, small polyphasic motor unit action potentials (MUAPs) and early recruitment.^{6 31} In addition, large polyphasic MUAPs can also be demonstrated in one-third of patients that has led to the misinterpretation of a neurogenic process and misdiagnosis of amyotrophic lateral sclerosis (ALS) in some patients.^{6 32 33} However, large polyphasic MUAPs can also be seen in myopathies (ie, PM, DM, muscular dystrophies) and probably reflects the chronicity of the disease process rather than a neurogenic aetiology.

IBM-FUNCTIONAL RATING SCALE (IBM-FRS)

We have developed a disease specific functional rating scale for IBM (see box).³⁴ This 10 point functional rating scale was

modified from the ALS functional rating scale.³⁵ The maximum score is 40, and the higher the score the better the functional status of the patient. The IBM-FRS addresses swallowing, handwriting, cutting food, handling utensils, dressing, hygiene, turning in bed, adjusting covers, sit to stand, walking and climbing stairs. The IBM-FRS correlates well with isometric strength and manual muscle testing, and we believe it should be utilised as an end point measurement in future IBM trials.

HISTOPATHOLOGY

Muscle biopsy characteristically reveals endomysial inflammation, small groups of atrophic fibres, eosinophilic cytoplasmic inclusions and muscle fibres with one or more rimmed vacuoles lined with granular material (fig 2).^{2 6 10 36} Congo red staining reveals that a small number of fibres, usually vacuolated ones, appear to have small amyloid deposits.^{37 38} We have observed that the number of vacuolated and amyloid positive fibres may increase with time in individual patients.³⁹ There are also an increased number of ragged red fibres and COX negative fibres in IBM compared with DM and PM patients and age matched controls.⁴⁰ Many of the myonuclei are enlarged, contain eosinophilic inclusions or are located within the vacuoles and appear to be exploding into the vacuoles themselves. Interestingly, the rimmed vacuoles immunostain with antibodies directed against the nuclear proteins such as emerin, lamin A/C, valosin containing protein (VCP), histone and 43 kDa TAR DNA binding protein, suggesting a component of the rimmed vacuoles may be secondary to remnants of destroyed myonuclei.⁴¹⁻⁴⁵ Various "Alzheimer characteristic proteins" are also evident by immunohistochemistry, mainly in vacuolated muscle fibres, but the significance is unclear (see pathogenesis section).

On electron microscopy, 15–21 nm cytoplasmic and intranuclear tubulofilaments may be appreciated although they can be difficult to find and a minimum of three vacuolated fibres often need to be scrutinised to confirm their presence (fig 3).⁶ Vacuolated fibres also contain cytoplasmic clusters of 6–10 nm amyloid-like fibrils.¹⁰ Repeat muscle biopsies may be required to demonstrate the rimmed vacuoles and abnormal tubulofilament

Inclusion Body Myositis–Functional Rating Scale (IBM–FRS)

1. Swallowing
 - 4 Normal
 - 3 Early eating problems—occasional choking
 - 2 Dietary consistency changes
 - 1 Frequent choking
 - 0 Needs tube feeding
2. Handwriting (*with dominant hand prior to IBM onset*)
 - 4 Normal
 - 3 Slow or sloppy; all words are legible
 - 2 Not all words are legible
 - 1 Able to grip pen but unable to write
 - 0 unable to grip pen
3. Cutting food and handling utensils
 - 4 Normal
 - 3 Somewhat slow and clumsy, but no help needed
 - 2 Can cut most foods, although clumsy and slow; some help needed
 - 1 Food must be cut by someone, but can still feed slowly
 - 0 Needs to be fed
4. Fine motor tasks (*opening doors, using keys, picking up small objects*)
 - 4 Independent
 - 3 Slow or clumsy in completing task
 - 2 Independent but requires modified techniques or assistive devices
 - 1 Frequently requires assistance from caregiver
 - 0 Unable
5. Dressing
 - 4 Normal
 - 3 Independent but with increased effort or decreased efficiency
 - 2 Independent but requires assistive devices or modified techniques (Velcro snaps, shirts without buttons, etc)
 - 1 Requires assistance from caregiver for some clothing items
 - 0 total dependence
6. Hygiene (bathing and toileting)
 - 4 Normal
 - 3 Independent but with increased effort or decreased activity
 - 2 Independent but requires use of assistive devices (shower chair, raised toilet seat, etc)
 - 1 Requires occasional assistance from caregiver
 - 0 Completely dependent
7. Turning in bed and adjusting covers
 - 4 Normal
 - 3 Somewhat slow and clumsy but no help needed
 - 2 Can turn alone or adjust sheets, but with great difficulty
 - 1 Can initiate, but not turn or adjust sheets alone
 - 0 Unable or requires total assistance
8. Sit to stand
 - 4 Independent (without use of arms)
 - 3 Performs with substitute motions (leaning forward, rocking) but without use of arms
 - 2 Requires use of arms
 - 1 requires assistance from a device or person
 - 0 Unable to stand

9. Walking
 - 4 Normal
 - 3 Slow or mild unsteadiness
 - 2 Intermittent use of an assistive device (ankle–foot orthosis, cane, walker)
 - 1 Dependent on assistive device
 - 0 Wheelchair dependent
10. Climbing stairs
 - 4 Normal
 - 3 Slow with hesitation or increased effort; uses hand rail intermittently
 - 2 Dependent on hand rail
 - 1 Dependent on hand rail and additional support (cane or person)
 - 0 Cannot climb stairs

or amyloid accumulation in order to histologically confirm the diagnosis of “definite” IBM.² This may be a result of sampling error and accounts for many cases of IBM being misdiagnosed as PM.

In IBM, there are endomysial inflammatory cell infiltrates composed of macrophages and CD8+ cytotoxic/suppressor T lymphocytes that surround and invade non-necrotic fibres.^{10–46} This is similar to the inflammatory cell process seen in PM. In addition, there are many myeloid dendritic cells in the endomysium that appear to surround non-necrotic muscle fibres.⁴⁷ These myeloid dendritic cells probably serve as antigen presenting cells and stimulate lymphocytes to develop antigen driven adaptive immune responses.

MHC class 1 antigens are expressed on necrotic and non-necrotic muscle fibres.⁴⁸ There is an oligoclonal pattern of gene rearrangement of the T cell receptor repertoire of the inflammatory cells although there is heterogeneity in the CDR3 domain.^{49–50} Persistence of this clonal restriction pattern has been observed on repeated muscle biopsies in some individual patients.⁵¹ These findings suggest that there is a continuous antigen driven attack against the muscle fibres.

RNA expression studies of IBM muscle demonstrate an increase in immunoglobulin related genes.^{52–53} This may be explained by the infiltration of oligoclonal plasma cells in IBM muscle tissue and studies have suggested an antigen driven B cell maturation and humoral response occurs in IBM.^{54–55} The pathogenic role, if any, of these plasma cells and immunoglobulins is unclear. Deposition of antibodies on muscle fibres has not been seen.

PROTEOMIC STUDIES IN MUSCLE

A recent study reported the results of mass spectrometry based proteomic profiling on muscle biopsy samples from 20 patients (IBM n = 8; PM n = 5; DM n = 4; normal n = 3) along with gene expression microarray studies that were performed in parallel on 13 diseased samples (IBM n = 5, PM n = 4, DM n = 4).⁵⁶ The most differentially reduced proteins in IBM compared with normal were those predominantly contained in fast twitch (type 2) muscle fibres. Structural proteins found to be decreased in IBM muscle included α -actinin-3 (present at one-tenth the normal amount), myosin binding protein C 2 (MYBPC2) (one-fifth normal), troponin T type 3 (TNNT3), myozenin 1

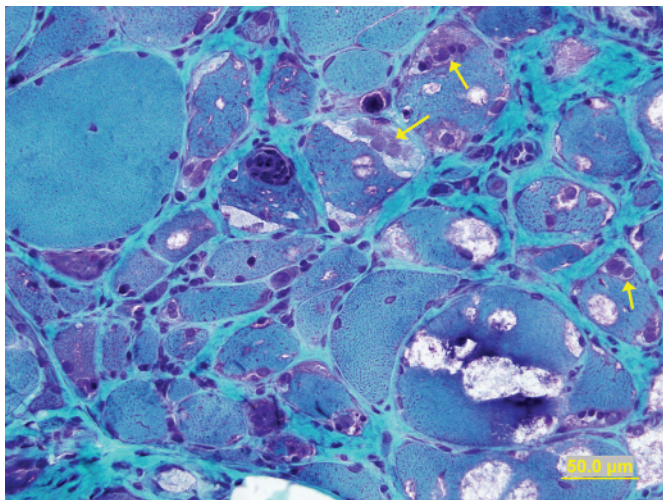


Figure 2 Muscle biopsy demonstrates scattered muscle fibres with rimmed vacuoles along with endomysial inflammatory cell infiltrate. Morphologically abnormal myonuclei can also be seen adjacent and within some of the rimmed vacuoles (arrows). Modified Gomori-trichrome stain.

(MYOZ1), myomesin 2 (MYOM2) and myosin heavy chain 1 (MYH1). The reduction in fast twitch structural proteins in IBM was not due to a generalised or non-specific reduction in muscle structural proteins. Nor was the loss of these fast twitch proteins felt to be simply a consequence of disease chronicity or degree of weakness in the biopsied muscle. The proteomic data were compared with gene transcriptional data for fast and slow twitch proteins. Although fast twitch proteins were reduced in comparison with slow twitch proteins, transcript levels were relatively similar. Therefore, the reduction in fast twitch proteins was due to either decreased translation or increased catabolism and not reduced transcription.

In comparison with normal muscle, the most differentially increased proteins in IBM muscle included the nuclear membrane protein lamin A/C, immunoglobulin heavy chains and filamin-alpha. As previously noted, lamin A/C is a myonuclear protein that is overexpressed with immunohistochemistry in vacuolated IBM muscle fibres. Other increased proteins in IBM muscle included several components of the

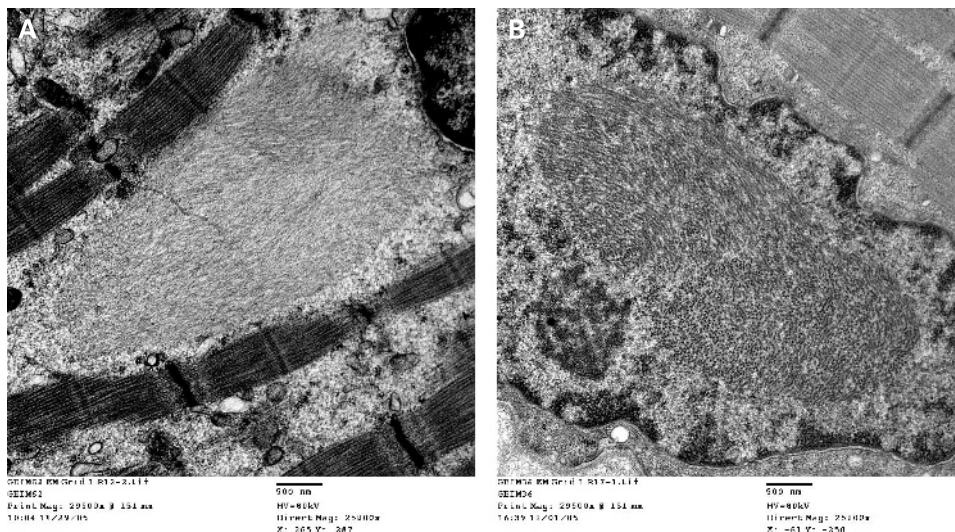
extracellular matrix, likely related to the increased endomysial fibrosis that was evident. Of note, not even one peptide from β -amyloid precursor protein (β -APP) was detected under conditions that allowed identification of approximately 2000 gene products which is important in the context of the next section.

PATHOGENESIS

The pathogenesis of IBM is unknown.^{21 57-60} It is unclear if IBM is a primary inflammatory myopathy like DM and PM, or a primary degenerative myopathy with a secondary inflammatory (such as seen in a variety of muscular dystrophies). The clonally restricted inflammatory cell infiltrate is suggestive of an autoimmune disorder mediated primarily by cytotoxic T cells. The frequency of muscle fibres invaded by inflammatory cells is usually greater than fibres with rimmed vacuoles or amyloid deposits, suggesting that the inflammatory response plays a more important role in the pathogenesis of IBM.⁶¹ The autoinvasive T cells in IBM release perforin granules, leading to pores on the muscle membrane that results in osmolysis. The role of the antigen driven humoral response evident by plasma cells and matured immunoglobulin transcripts detected in IBM muscle is not known.^{54 55} One might speculate that the antigen(s) driving the T cell response and the plasma cells may be the same. It may be easier to identify what the immunoglobulins produced in the muscle are being directed against than determining what the T cells are targeting. Whether or not the monoclonal proteins in the serum found in approximately 20% of patients with IBM are somehow related to the inflammatory process in the muscle is worth investigating further.

The lack of significant clinical response with various immunosuppressives argues against IBM being a primary autoimmune disorder. We treated eight patients with IBM for 6-24 months with immunosuppressive medications.³⁹ None of the patients improved in strength or function despite lower serum CK levels and reduced inflammation on the post-treatment muscle biopsies. Interestingly, as noted previously, the amount of vacuolated muscle fibres and fibres with amyloid deposition were increased in the follow-up biopsies. Therefore, we suggested that inflammation may play a secondary role in the pathogenesis of IBM.

Figure 3 Electron microscopy reveals tubulofilamentous inclusions in the sarcoplasm (A) and within a myonucleus (B). With permission from: Amato AA, Russell J. *Neuromuscular disease*. New York: McGraw-Hill, 2008:697.



IBM could be a degenerative disorder of muscle. The nature of this degenerative process is not known and is a matter of great debate. Much attention has focused on so-called "Alzheimer characteristic proteins" (eg, β -amyloid, C and N terminal epitopes of β -APP, hyperphosphorylated tau, prion protein (PrP^c), apolipoprotein E, (1-antichymotrypsin, ubiquitin, and neurofilament heavy chain) have been reported in vacuolated muscle fibres using immunohistochemistry.^{10 57 62-67} A prevailing theory is that there is an overproduction of β -APP in muscle fibres that is somehow cleaved into abnormal β -amyloid and the accumulation of the latter is somehow toxic to muscle fibres.⁶³⁻⁶⁵ Furthermore, some have suggested that cytokines released by inflammatory cells may be responsible for inducing the over-expression of β -APP in muscle fibres.⁶⁶

However, as pointed out in recent articles by Greenberg, this theory is very controversial.^{59 68} The interpretation that β -amyloid accumulates in IBM myofibres is based on its presence by immunohistochemical methods using antibodies that may cross react with β -APP. Since β -amyloid is a part of the β -APP, antibodies directed against β -amyloid may also bind to β -APP or any subfragment that contains β -amyloid. Therefore, western blot is necessary to confirm that such antibodies are binding a protein of the same molecular weight as β -amyloid. However, no one has reported a western blot on IBM muscle revealing a 4 kDa band (the approximate mass of β -amyloid) immunoreactive using any anti- β -APP or anti- β -amyloid antibody.

It is not well appreciated that β -APP is secreted by inflammatory cells. Since there is prominent inflammatory cell infiltrate in IBM muscle it would not be surprising to find that increased β -APP transcript and protein in whole muscle preparations correlate with chemokines and cytokines as recently reported.⁶⁵ This does not mean that the muscle fibres themselves are overproducing β -APP. Furthermore, even investigators who support the β -amyloid toxicity hypothesis have found in their own studies that β -amyloid and β -APP transcript and protein were also evident in muscle tissue from patients with PM, DM, various types of muscular dystrophy and even amyotrophic lateral sclerosis. An even greater amount of β -APP transcript was found in DM in one recent study.⁶⁶ We have found similar degrees of increased mRNA of all the so-called Alzheimer characteristic proteins in muscle biopsies of PM and DM patients.⁵² Furthermore, as previously noted, mass spectrometry based proteomic profiling failed to demonstrate accumulation of even a single peptide from β -APP in IBM muscle tissue.⁵⁶ Given these observations, we find it hard to imagine that increased β -APP or an abnormally cleaved β -amyloid fragment is somehow integral to the pathogenesis of IBM. A similar problem exists with reports that "tau" abnormality accumulates in IBM muscle fibres and may somehow be involved in the pathogenesis of IBM. So called "anti-tau" antibodies (eg, SMI-31) cross react with other proteins that are present in normal myonuclei. Western blot studies in IBM muscle demonstrate immunoreactivity against nuclear proteins outside the region expected for phosphorylated tau.⁶⁹

Of note, rimmed vacuoles and tubulofilamentous inclusions are found in other myopathies, including various types of hereditary inclusion body myopathy, oculopharyngeal muscular dystrophy and Emery–Dreifuss muscular dystrophy. It is interesting in regard to oculopharyngeal muscular dystrophy and Emery–Dreifuss muscular dystrophy that the mutated proteins localise to nuclei. Given the rimmed vacuoles immunostain with antibodies directed against the nuclear proteins such as emerin, lamin A/C, VCP and histone 1 and that myonuclei often are abnormal and filled with neurofilaments on EM, we

would speculate that myonuclear degeneration is probably one of the earliest features of the disease and must be directly related to the pathogenesis.^{41-44 59}

Ragged red fibres and mitochondrial DNA mutations are more frequent in IBM patients than in other inflammatory myopathies and in age matched controls but are thought to be secondary abnormalities.^{10 40 70} Vacuolated muscle fibres express increased nitrotyrosine and both the inducible and nuclear forms of nitric oxide synthase, suggesting that nitric oxide induced oxidative stress may play a role in muscle fibre destruction in IBM.⁷¹ Of note, B crystallin, a member of the heat shock protein family, is also overexpressed in both normal as well as abnormal muscle fibres, indicating that the pathological stress is acting upstream from to the development of rimmed vacuoles and the accumulation of "Alzheimer-like" proteins, nitric oxide synthase expression and mitochondrial mutations.⁷²

A viral aetiology has been speculated to be involved in the pathogenesis of IBM but has never been proven. Chronic persistent mumps was previously hypothesised based on immunostaining of inclusions by anti-mumps antibodies⁷³ but was subsequently rejected after in situ hybridisation and polymerase chain reaction studies failed to confirm mumps infection.^{74 75} Interestingly, patients with retroviral infections (HIV and HTLV-1) and post-polio syndrome can have histological abnormalities on muscle biopsy similar to IBM.^{76 77}

DIFFERENTIAL DIAGNOSIS

Many of the patients we have seen with IBM were previously diagnosed as having PM.² It is important to remember that because of sampling error, histopathological confirmation of IBM is not always possible. The presence of slowly progressive, asymmetric, quadriceps and wrist/finger flexor weakness and atrophy in a patient over 50 years of age strongly suggests the diagnosis of IBM, even in the absence of histological confirmation.

The asymmetric muscle atrophy and distal weakness unfortunately can lead to the misdiagnosis of ALS. However, the muscle groups affected early are different in IBM compared with ALS. Again in IBM there is atrophy of the flexor forearm compartment but the hand intrinsics (thenar and hypotenar eminence) are spared, in contrast with ALS in which atrophy in the arms is usually first seen in the hand intrinsics. In addition, fasciculations, cramps, hyperreflexia, spasticity and dysarthria, all cardinal features of ALS, do not occur in IBM. The relatively mild to moderate dysphagia seen in IBM is usually easily distinguished from the severe bulbar involvement of ALS.

Rimmed vacuoles, amyloid deposition and tubulofilamentous inclusions are not specific for inclusion body *myositis*. They are characteristically observed in patients with various forms of hereditary inclusion body *myopathy* (h-IBM). Usually, these biopsies are non-inflammatory but occasionally there are inflammatory cell infiltrates present and can lead to misdiagnosis as sporadic inclusion body *myositis*. Therefore, it is important to recognise the clinical phenotypes which are distinct.

The most common form of h-IBM is inherited in an autosomal recessive fashion. It was initially reported in Middle Eastern Jews and in Japan but it occurs throughout the world.⁷⁸⁻⁸⁰ Patients usually present in early adult life (less than age 30 years) with progressive foot drop. The weakness gradually progresses but unlike typical sporadic IBM the quadriceps muscles are relatively spared. The myopathy is caused by mutations in the UDP-N-acetylglucosamine

2-epimerase/N-N-acetylmannosamine kinase (*GNE*) gene. Autosomal dominant h-IBM is less common and the clinical phenotype is more variable. One form of autosomal dominant h-IBM caused by mutations in the VCP gene and can be associated with Paget disease and frontotemporal dementia.^{81 82} Onset can be in early childhood to late adult life. Proximal and distal along with ventilatory muscle weakness can be seen. Scapular winging is common. Patients with Paget disease may complain of bone pain and have an elevated serum alkaline phosphatase level. h-IBM type 3 is a rare autosomal dominant disorder that usually presents with congenital arthrogryposis.^{83 84} Mild proximal weakness and ophthalmoparesis begin later in adulthood. This myopathy has been linked to mutations in the myosin heavy IIa gene. Rimmed vacuoles and various inclusions are also commonly seen in other types of muscular dystrophy, including LGMD1A (myotilinopathy), LGMD 2J (titinopathy), oculopharyngeal dystrophy, Welander distal myopathy and the various types of myofibrillar myopathy.

PROGNOSIS

Life expectancy is not significantly altered in IBM. The myopathy is slowly progressive and unfortunately it is not responsive to immunosuppressive or immunomodulating therapies. Some patients become wheelchair bound within 10–15 years.⁶

TREATMENT

We and others have not found any clinically significant improvement in strength of function with prednisone or other secondline agents in patients with IBM.^{2 6 85} However, a few retrospective, unblinded studies reported mild or transient improvement with prednisone.^{86 87} A partial response to prednisone was noted in 40–58% of IBM patients although none had complete return of strength. Careful review of these retrospective, unblinded studies shows that the investigators considered *subjective* improvement or lower serum CK levels with treatment a “positive” response. No demonstration of objective improvement in muscle strength was necessary. These investigators performed a small (11 patients), unblinded, prospective, crossover designed study comparing prednisone plus azathioprine plus oral methotrexate to prednisone plus intravenous methotrexate. There was no clinically significant change in strength over the 6 month treatment period in both study arms, although they found the serum CK levels decreased in 66–70% of the patients. On this basis, the investigators concluded that the combination of immunosuppressive medications stabilised the disease process. However, because IBM is a slowly progressive disorder, the trial lasted only 6 months, and the study was neither unblinded nor placebo controlled, their assertion that immunosuppressive medications stabilise the course of IBM was clearly premature. A more recent controlled trial of methotrexate versus placebo in IBM showed no benefit from the methotrexate therapy.⁸⁸ In this 48 week study, methotrexate did not slow down progression of muscle weakness although CK levels decreased, which is a phenomenon we also have appreciated.⁸⁹ A pilot study of anti-T lymphocyte inhibitor showed no definite benefit.⁸⁹ One group has suggested ciclosporin or tacrolimus may be beneficial if there are other features of autoimmune disease.⁹⁰

The use of intravenous immunoglobulin (IVIG) for IBM remains somewhat controversial. A mild improvement in muscle strength was reported in three of four IBM patients treated with IVIG.⁹¹ However, we were unable to document any significant clinical improvement in nine IBM patients treated

with IVIG.⁸¹ Subsequently, double blind, placebo controlled studies of IVIG in IBM revealed no significant clinical improvement in muscle strength.^{92–94} In general, we do not advocate the use of IVIG for IBM. Although IVIG still appears to be frequently used by some practitioners for IBM, we believe the evidence suggests it is not an effective therapy for this disease.

The use of tumour necrosis factor inhibitors for IBM has received limited attention. We performed a small pilot trial of the tumour necrosis factor α blocker, etanercept, in nine IBM patients.⁹⁵ While there was a trend toward a slower decline of grip strength over 12 months compared with historical controls, overall etanercept did not show a significant benefit. An ongoing small placebo controlled, randomised trial of etanercept in IBM is being conducted at Washington University (see www.clinicaltrials.gov).

The Muscle Study Group conducted two placebo controlled trials using β -interferon 1A in IBM, and both were negative trials.^{96 97} A small randomised pilot trial of oxandrolone, an androgen receptor agonist, suggests this drug needed to be studied further as it may have had a modest benefit in muscle strength.⁹⁸ At this point, we are not aware of any planned trials of this or other androgen receptor agonists. A home exercise programme for IBM patients has been studied, and the authors reported that IBM patients demonstrated actual improvement in strength.⁹⁹ This line of research clearly needs further study.

We are aware of two other small therapeutic pilot studies for IBM. One involves arimoclomol, a heat shock protein inducer, which was shown to be safe in a pilot safety study for patients with ALS.¹⁰⁰ The rationale is that increasing heat shock protein may assist in ridding the cells of abnormally folded proteins that may be accumulating in IBM muscle fibres. This small pilot study is being conducted at the University of Kansas Medical Centre and at the Institute of Neurology, London, UK (see www.clinicaltrials.gov). The other is a pilot study with the drug lithium, which is also being used in a clinical trial for ALS based on the potential for lithium to serve as a neuroprotective agent.¹⁰¹ A study of lithium in a transgenic model of IBM that overexpresses β -APP demonstrated a trend in improvement in motor function but this was not statistically significant.¹⁰² The use of these so-called animal models of IBM to understand the pathogenesis of IBM and select drugs to try in clinical trials has to be viewed cautiously given the lack of strong scientific evidence that either β -APP or β -amyloid are directly involved in causing IBM (see pathogenesis section).

SUMMARY

IBM can be distinguished clinically, histologically and pathogenically within the larger group of idiopathic inflammatory myopathy. The pathogenesis of IBM remains unknown. Unfortunately, IBM is generally refractory to therapy. Further research into the pathogenesis, along with both preliminary small pilot trials and larger double blind, placebo controlled efficacy trials, are needed to make progress in our understanding and therapeutic approach for this disorder.

Competing interests: None.

Patient consent: Obtained.

Provenance and peer review: Commissioned; externally peer reviewed.

REFERENCES

1. Dalakas MC. Polymyositis, dermatomyositis and inclusion-body myositis. *N Engl J Med* 1991;**325**:1487–98.

2. **Amato AA**, Gronseth GS, Jackson CE, *et al*. Inclusion body myositis: Clinical and pathological boundaries. *Ann Neurol* 1996;**40**:581–6.
3. **Amato AA**, Barohn RJ. Idiopathic inflammatory myopathies. *Neural Clin* 1997;**15**:615–48.
4. **Needham M**, Mastaglia FL. Inclusion body myositis: current pathogenetic concepts and diagnostic and therapeutic approaches. *Lancet Neurol* 2007;**6**:620–31.
5. **Amato AA**, Russell J. *Neuromuscular disease*. New York: McGraw-Hill, 2008:681–719.
6. **Lotz BP**, Engel AG, Nishino H, *et al*. Inclusion body myositis: observation in 40 patients. *Brain* 1989;**112**:727–47.
7. **Mhiri C**, Gherardi R. Inclusion body myositis in French patients. A clinicopathological evaluation. *Neuropathol Appl Neurobiol* 1990;**16**:333–44.
8. **Badrising UA**, Maat-Schieman ML, van Houwelingen JC, *et al*. Inclusion body myositis: clinical features and clinical course of the disease in 64 patients. *J Neurol* 2005;**252**:1448–54.
9. **Barohn RJ**, Amato AA. Inclusion body myositis. *Curr Treat Options Neurol* 2000;**2**:7–12.
10. **Griggs RC**, Askansas V, DiMauro S, *et al*. Inclusion body myositis and myopathies. *Ann Neurol* 1995;**38**:705–13.
11. **Bohan A**, Peter JB. Polymyositis and dermatomyositis (first of two parts). *N Engl J Med* 1975;**292**:344–7.
12. **Bohan A**, Peter JB. Polymyositis and dermatomyositis (second of two parts). *N Engl J Med* 1975;**292**:403–7.
13. **Bohan A**, Peter JB, Bowman RL, *et al*. Computer-assisted analysis of 153 patients with polymyositis and dermatomyositis. *Medicine (Baltimore)* 1977;**56**:255–86.
14. **Briemberg HR**, Amato AA. Dermatomyositis and polymyositis. *Curr Treat Options Neurol* 2003;**5**:349–56.
15. **van der Meulen MF**, Bronner IM, Hoogendijk JE, *et al*. Polymyositis: an overdiagnosed entity. *Neurology* 2003;**61**:316–21.
16. **Hoogendijk JE**, Amato AA, Lecky BR, *et al*. 119th ENMC international workshop: trial design in adult idiopathic inflammatory myopathies, with the exception of inclusion body myositis, 10–12 October 2003, Naarden, The Netherlands. *Neuromuscul Disord* 2004;**14**:337–45.
17. **Badrising UA**, Maat-Schieman M, van Duinen SG, *et al*. Epidemiology of inclusion body myositis in the Netherlands: a nationwide study. *Neurology* 2000;**55**:1385–7.
18. **Lindberg C**, Persson LI, Bjorkander J, *et al*. Inclusion body myositis: clinical, morphological, physiological and laboratory findings in 18 cases. *Acta Neurol Scand* 1994;**89**:123–31.
19. **Wilson FC**, Ytterberg SR, St Sauver JL, *et al*. Epidemiology of sporadic inclusion body myositis and polymyositis in Olmsted County, Minnesota. *J Rheumatol* 2008;**35**:445–7.
20. **Felice KJ**, Relva GM, Conway SR. Further observations on forearm flexor weakness in inclusion body myositis. *Muscle Nerve* 1998;**21**:659–61.
21. **Needham M**, Mastaglia FL. Sporadic inclusion body myositis: a continuing puzzle. *Neuromusc Disord* 2008;**18**:6–16.
22. **Verma A**, Bradley WG, Adesina AM, *et al*. Inclusion body myositis with cricopharyngeus muscle involvement and severe dysphagia. *Muscle Nerve* 1991;**14**:470–3.
23. **Darrow DH**, Hoffman HT, Barnes GJ, *et al*. Management of dysphagia in inclusion body myositis. *Arch Otolaryngol Head Neck Surg* 1992;**118**:313–17.
24. **Danon MJ**, Perurena OH, Ronan S, *et al*. Inclusion body myositis associated with systemic sarcoidosis. *Can J Neurol Sci* 1986;**13**:334–6.
25. **Koffman BM**, Rugiero M, Dalakas MC. Immune-mediated conditions and antibodies associated with sporadic inclusion body myositis. *Muscle Nerve* 1998;**21**:115–17.
26. **Love LA**, Leff RL, Fraser DD, *et al*. A new approach to the classification of idiopathic inflammatory myopathy: myositis-specific autoantibodies define useful homogeneous patient groups. *Medicine (Baltimore)* 1991;**70**:360–74.
27. **Hengstman GJ**, van Engelen BG, Badrising UA, *et al*. Presence of the anti-Jo-1 autoantibody excludes inclusion body myositis. *Ann Neurol* 1998;**44**:423.
28. **Garlepp MJ**, Laing B, Zilko PJ, *et al*. HLA associations with inclusion body myositis. *Clin Exp Immunol* 1994;**98**:40–5.
29. **Fraser DD**, Frank JA, Dalakas M, *et al*. Magnetic resonance imaging in the idiopathic inflammatory myopathies. *J Rheumatol* 1991;**18**:1693–700.
30. **Sekul EA**, Chow C, Dalakas MC. Magnetic resonance imaging of the forearm as a diagnostic aid in patients with sporadic inclusion body myositis. *Neurology* 1993;**48**:863–6.
31. **Amato A**, Dumitru D. *Acquired myopathies*. Philadelphia: Hanley and Belfus, 2002.
32. **Eisen A**, Berry K, Gibson G. Inclusion body myositis (IBM): myopathy or neuropathy? *Neurology* 1983;**33**:1109–14.
33. **Joy JL**, Oh SJ, Baysal AI. Electrophysiological spectrum of inclusion body myositis. *Muscle Nerve* 1990;**13**:949–51.
34. **Jackson CE**, Barohn RJ, Gronseth G, *et al*. Inclusion body myositis functional rating scale: a reliable and valid measure of disease severity. *Muscle Nerve* 2008;**37**:473–6.
35. **Cedarbaum JM**, Stambler N, Malta E, *et al*. The ALSFRS-R: a revised ALS functional rating scale that incorporates assessments of respiratory function. BDNF ALS Study Group (Phase II/III). *J Neurol Sci* 1999;**169**:13–21.
36. **Chahin N**, Engel AG. Correlation of muscle biopsy, clinical course, and outcome in PM and sporadic IBM. *Neurology* 2008;**70**:418–24.
37. **Mendell JR**, Sahenk Z, Gales T, *et al*. Amyloid filaments in inclusion body myositis. Novel findings provide insight into nature of filaments. *Arch Neurol* 1991;**48**:1229–34.
38. **Askanas V**, Engel WK, Alvarez RB. Enhanced detection of congo-red-positive amyloid deposits in muscle fibers of inclusion body myositis and brain of Alzheimer's disease using fluorescence technique. *Neurology* 1993;**43**:1265–7.
39. **Barohn RJ**, Amato AA, Sahenk Z, *et al*. Inclusion body myositis: explanation for poor response to immunosuppressive therapy. *Neurology* 1991;**45**:1302–4.
40. **Rifai Z**, Welle S, Kamp C, *et al*. Ragged red fibers in normal aging and inflammatory myopathy. *Ann Neurol* 1995;**37**:24–9.
41. **Greenberg SA**, Pinkus JL, Amato AA. Nuclear membrane proteins are present within rimmed vacuoles in inclusion-body myositis. *Muscle Nerve* 2006;**34**:406–16.
42. **Greenberg SA**, Watts GD, Kimonis VE, *et al*. Nuclear localization of valosin-containing protein in normal muscle and muscle affected by inclusion-body myositis. *Muscle Nerve* 2007;**36**:447–54.
43. **Nakano S**, Shinde A, Fujita K, *et al*. Histone H1 is released from myonuclei and present in rimmed vacuoles with DNA in inclusion body myositis. *Neuromuscul Disord* 2008;**18**:27–33.
44. **Weihl CC**, Temiz P, Miller SE, *et al*. TDP-43 accumulation in inclusion body myopathy muscle suggests a common pathogenic mechanism with frontotemporal dementia. *Journal Neurol Neurosurg Psychiatry* 2008;**79**:1186–9.
45. **Salajegheh M**, Pinkus JL, Taylor JP, *et al*. Sarcoplasmic redistribution of TDP-43 in inclusion body myositis. *Muscle Nerve* 2009;**40**:19–36.
46. **Engel AG**, Arahata K. Monoclonal antibody analysis of mononuclear cells in myopathies. II: Phenotypes of autoinvasive cells in polymyositis and inclusion body myositis. *Ann Neurol* 1984;**16**:209–15.
47. **Greenberg SA**, Pinkus GS, Amato AA, *et al*. Myeloid dendritic cells in inclusion-body myositis and polymyositis. *Muscle Nerve* 2007;**35**:17–23.
48. **Emslie-Smith AM**, Arahata K, Engel AG. Major histocompatibility complex class I antigen expression, immunolocalization of interferon subtypes, and T cell-mediated cytotoxicity in myopathies. *Hum Pathol* 1989;**20**:224–31.
49. **Mantegazza R**, Andreeta F, Bernasconi P, *et al*. Analysis of T cell receptor repertoire of muscle-infiltrating T lymphocytes in polymyositis. Restricted V alpha/beta rearrangements may indicate antigen-driven selection. *J Clin Invest* 1993;**91**:2880–6.
50. **O'Hanlon TP**, Dalakas MC, Plotz PH, *et al*. The alpha beta T-cell receptor repertoire in inclusion body myositis: diverse patterns of gene expression by muscle-infiltrating lymphocytes. *J Autoimmun* 1994;**7**:321–33.
51. **Amemiya K**, Granger RP, Dalakas MC. Clonal restriction of T-cell receptor expression by infiltrating lymphocytes in inclusion body myositis persists over time. Studies in repeated muscle biopsies. *Brain* 2000;**123**:2030–9.
52. **Greenberg SA**, Sanoudou D, Haslett JN, *et al*. Molecular profiles of inflammatory myopathies. *Neurology* 2002;**59**:1170–82.
53. **Greenberg SA**, Bradshaw EM, Pinkus JL, *et al*. Plasma cells in muscle in inclusion body myositis and polymyositis. *Neurology* 2005;**65**:1782–7.
54. **Greenberg SA**. A gene expression approach to study perturbed pathways in myositis. *Curr Opin Rheumatol* 2007;**19**:536–41.
55. **Bradshaw EM**, Orihuela A, McArdel SL, *et al*. A local antigen-driven humoral response is present in the inflammatory myopathies. *J Immunol* 2007;**178**:547–56.
56. **Parker S**, Kong SW, Walsh RJ, *et al*. Fast-twitch sarcomeric and glycolytic enzyme protein loss in inclusion body myositis. *Muscle Nerve* 2009;**39**:739–53.
57. **Askanas V**, Engel WK. Inclusion-body myositis, a multifactorial muscle disease associated with aging: current concepts of pathogenesis. *Curr Opin Rheumatol* 2007;**19**:550–9.
58. **Greenberg SA**. Proposed immunologic models of the inflammatory myopathies and potential therapeutic implications. *Neurology* 2007;**69**:2008–19.
59. **Greenberg SA**. Inclusion body myositis: review of recent literature. *Curr Neurol Neurosci Rep* 2009;**9**:83–9.
60. **Dalakas MC**. Interplay between inflammation and degeneration: using inclusion body myositis to study "neuroinflammation". *Ann Neurol* 2008;**64**:15–24.
61. **Pruitt JN II**, Showalter CJ, Engel AG. Sporadic inclusion body myositis: counts of different types of abnormal fibers. *Ann Neurol* 1996;**39**:139–43.
62. **Greenberg SA**, Pinkus JL, Pinkus GS, *et al*. Interferon-alpha/beta-mediated innate immune mechanisms in dermatomyositis. *Ann Neurol* 2005;**57**:664–78.
63. **Askanas V**, Alvarez RB, Engel WK. beta-Amyloid precursor epitopes in muscle fibers of inclusion body myositis. *Ann Neurol* 1993;**34**:551–60.
64. **Askanas V**, Engel WK. Proposed pathogenetic cascade of inclusion-body myositis: importance of amyloid-beta, misfolded proteins, predisposing genes, and aging. *Curr Opin Rheumatol* 2003;**15**:737–44.
65. **Askanas V**, Engel WK. Inclusion-body myositis: a myodegenerative conformational disorder associated with Abeta, protein misfolding, and proteasome inhibition. *Neurology* 2006;**66**(Suppl 1):S39–48.
66. **Schmidt J**, Barthel K, Wrede A, *et al*. Interrelation of inflammation and APP in sIBM:IL-1 beta induces accumulation of beta-amyloid in skeletal muscle. *Brain* 2008;**131**:1228–40.
67. **Lunemann JD**, Schmidt J, Schmid D, *et al*. Beta-amyloid is a substrate of autophagy in sporadic inclusion body myositis. *Ann Neurol* 2007;**61**:476–83.
68. **Greenberg SA**. How citation distortions create unfounded authority: analysis of a citation network. *BMJ* 2009;**39**:b2680.
69. **Salajegheh M**, Pinkus JL, Nazareno R, *et al*. Nature of "Tau" immunoreactivity in normal myonuclei and inclusion body myositis. *Muscle Nerve* 2009 (22 July Epub ahead of print).
70. **Oldfors A**, Moslemi AR, Fyhr IM, *et al*. Mitochondrial DNA deletions in muscle fibers in inclusion body myositis. *J Neuropathol Exp Neurol* 1995;**54**:581–7.
71. **Yang CC**, Alvarez RB, Engel WK, *et al*. Increase of nitric oxide synthases and nitrotyrosine in inclusion-body myositis. *Neuroreport* 1996;**8**:153–8.

72. **Banwell BL**, Engel AG. AlphaB-crystallin immunolocalization yields new insights into inclusion body myositis. *Neurology* 2000;**54**:1033–41.
73. **Chou SM**. Inclusion body myositis: a chronic persistent mumps myositis? *Hum Pathol* 1986;**17**:765–77.
74. **Nishino H**, Engel AG, Rima BK. Inclusion body myositis: the mumps virus hypothesis. *Ann Neurol* 1989;**25**:260–4.
75. **Kallajoki M**, Hyypia T, Halonen P, *et al*. Inclusion body myositis and paramyxoviruses. *Hum Pathol* 1991;**22**:29–32.
76. **Cupler EJ**, Leon-Monzon M, Miller J, *et al*. Inclusion body myositis in HIV-1 and HTLV-1 infected patients. *Brian* 1996;**119**:1887–93.
77. **Semino-Mora C**, Dalakas MC. Rimmed vacuoles with beta-amyloid and ubiquitinated filamentous deposits in the muscles of patients with long-standing denervation (postpoliomyelitis muscular atrophy): similarities with inclusion body myositis. *Hum Pathol* 1998;**29**:1128–33.
78. **Sunohara N**, Nonaka I, Kamei N, *et al*. Distal myopathy with rimmed vacuole formation. A follow-up study. *Brain* 1989;**112**:65–83.
79. **Argov Z**, Eisenberg I, Grabov-Nardini G, *et al*. Hereditary inclusion body myopathy: The Middle Eastern genetic cluster. *Neurology* 2003;**60**:1519–23.
80. **Eisenberg I**, Avidan N, Potikha T, *et al*. The UDP-N-acetylglucosamine 2-epimerase/N-N-acetylmannosamine kinase gene is mutated in recessive hereditary inclusion body myositis. *Nat Genet* 2001;**29**:83–7.
81. **Watts GD**, Wymer J, Kovach MJ, *et al*. Inclusion body myopathy associated with Paget disease of bone and frontotemporal dementia is caused by mutant valosin-containing protein. *Nat Genet* 2004;**36**:377–81.
82. **Kimonis VE**, Mehta SG, Fulchiero EC, *et al*. Clinical studies in familial VCP myopathy associated with Paget disease of bone and frontotemporal dementia. *Am J Med Genet* 2008;**146A**:745–57.
83. **Martinsson T**, Oldfors A, Darin N, *et al*. Autosomal dominant myopathy: Missense mutation (Glu-706 to Lys) in the myosin heavy IIa gene. *Proc Natl Acad Sci USA* 2000;**97**:14614–19.
84. **Amato AA**, Barohn RJ, Jackson CE, *et al*. Inclusion body myositis: treatment with intravenous immunoglobulin. *Neurology* 1994;**44**:1516–18.
85. **Dalakas MC**. Inflammatory disorders of muscle: progress in polymyositis, dermatomyositis and inclusion body myositis. *Curr Opin Neurol* 2004;**17**:561–7.
86. **Joffe MM**, Love LA, Leff RL, *et al*. Drug therapy of the idiopathic inflammatory myopathies: predictors of response to prednisone, azathioprine, and methotrexate and a comparison of their efficacy. *Am J Med* 1993;**94**:379–87.
87. **Leff RL**, Miller FW, Hicks J, *et al*. The treatment of inclusion body myositis: a retrospective and a randomized, prospective trial of immunosuppressive therapy. *Medicine* 1993;**72**:225–35.
88. **Badrising UA**, Maat-Shieman ML, Ferrari MD, *et al*. Comparison of weakness progression in inclusion body myositis during treatment with methotrexate or placebo. *Ann Neurol* 2002;**51**:369–72.
89. **Lindberg C**, Trysberg E, Tarkowski A, *et al*. Anti-T-lymphocyte globulin treatment in inclusion body myositis: a randomized pilot study. *Neurology* 2003;**61**:260–2.
90. **Quartuccio L**, De Marchi G, Scott CA, *et al*. Treatment of inclusion body myositis with cyclosporine-A or tacrolimus: successful long-term management in patients with earlier active disease and concomitant autoimmune features. *Clin Exp Rheumatol* 2007;**25**:246–51.
91. **Soueidan SA**, Dalakas MC. Treatment of inclusion-body myositis with high-dose intravenous immunoglobulin. *Neurology* 1993;**43**:876–9.
92. **Dalakas MC**, Sonies B, Dambrosia J, *et al*. Treatment of inclusion-body myositis with IVIg: a double-blind, placebo-controlled study. *Neurology* 1997;**48**:712–16.
93. **Dalakas MC**, Koffman B, Fujii M, *et al*. A controlled study of intravenous immunoglobulin combined with prednisone in the treatment of IBM. *Neurology* 2001;**56**:323–7.
94. **Walker MC**, Lochmuller H, Toepfer M, *et al*. High-dose immunoglobulin therapy in sporadic inclusion body myositis: a double-blind, placebo-controlled study. *J Neural* 2000;**247**:22–8.
95. **Barohn RJ**, Herbelin L, Kissel JT, *et al*. Pilot trial of etanercept in the treatment of inclusion-body myositis. *Neurology* 2006;**66**(Suppl 1):S123–4.
96. **Muscle Study Group**. Randomized pilot trial of beta1NF1a (Avonex) in patients with inclusion body myositis. *Neurology* 2001;**57**:1566–70.
97. **Muscle Study Group**. Randomized pilot trial of high-dose beta1NF1a in patients with inclusion body myositis. *Neurology* 2004;**63**:718–20.
98. **Rutkove SB**, Parker RA, Nardin RA, *et al*. A pilot randomized trial of oxandrolone in inclusion body myositis. *Neurology* 2002;**58**:1081–7.
99. **Johnson L**, Edwards D, Walters S, *et al*. The effectiveness of an individualized, home-based functional exercise program for patients with sporadic inclusion body myositis. *J Clin Neuromusc Dis* 2007;**8**:187–94.
100. **Cudkowicz ME**, Shefner JM, Simpson E, *et al*. Arimoclochol at dosages up to 300 mg/day is well tolerated and safe in amyotrophic lateral sclerosis. *Muscle Nerve* 2008;**38**:837–44.
101. **Fornai F**, Longone P, Cafaro L, *et al*. Lithium delays progression of amyotrophic lateral sclerosis. *Proc Natl Acad Sci U S A* 2008;**105**:2052–7.
102. **Kitazawa M**, Trinh DN, Laferla FM, *et al*. Inflammation induced tau pathology in inclusion body myositis model via glycogen synthetase kinase-3beta. *Ann Neurol* 2008;**64**:15–24.

BMJ Masterclasses

BMJ Masterclasses are educational meetings designed specifically to meet the learning needs of doctors. They help doctors keep up to date with the latest evidence and recent guidelines in major clinical areas, enabling them to use the latest evidence to make better decisions. The latest evidence, recent guidelines and best practice are delivered in an interactive and informative manner by leading experts. The speakers are specifically chosen as highly-skilled communicators who can authoritatively enthuse the audience and interpret the latest research and guidelines into practical tips for busy doctors. BMJ Masterclasses have proved a huge hit with clinicians, with many saying they have influenced their clinical practice.

<http://masterclasses.bmj.com/>

BMJ
masterclasses
Putting the latest evidence based medicine into practice